

Degree in dentistry

Final degree project

Class of 2021-22

**Transcrestal sinus floor elevation with or without
bone graft: a systematic review**

Presented by: Matteo Nardinelli

Tutor: Alberto Molina Palomero

Table of contents

I. LIST OF SIGNS AND ACRONYMS	1
II. ABSTRACT	1
III. KEYWORDS.....	1
1. INTRODUCTION	1
1.1. SINUS LIFT SURGERY	1
1.2. MAXILLARY SINUS.....	2
1.2.1. <i>Physiology and histology</i>	2
1.2.2. <i>Mucosa</i>	3
1.2.3. <i>Osteology</i>	3
1.2.4. <i>Innervation</i>	4
1.2.5. <i>Blood supply</i>	4
1.2.6. <i>Sinus pneumatization and bone loss in the posterior maxilla</i>	4
1.3. INDICATION FOR SINUS LIFT SURGERY.....	5
1.3.1. <i>Classifications of bone loss pattern</i>	6
1.4. PRE-OPERATIVE STUDY	8
1.5. SINUS LIFT SURGERY, THE LATERAL APPROACH	9
1.6. SINUS LIFT SURGERY, THE TRANSCRESTAL APPROACH	10
1.6.1. <i>Different techniques for the crestal approach</i>	11
2. JUSTIFICATION, HYPOTHESIS, AND OBJECTIVES	13
3. MATERIALS AND METHODS	14
3.1. SELECTION OF STUDIES - P.I.C.O. QUESTION (FOCUSED QUESTION)	14
3.2. SEARCH STRATEGY AND SOURCES OF DATA	15
3.3. PROCESS FOR THE SELECTION OF THE STUDIES	17
3.4. SCREENING FOR ARTICLE SELECTION	17
3.5. RISK OF BIAS ASSESMENT	17
3.6. DATA EXTRACTION.....	18
4. RESULTS	19
4.1 STUDY SELECTION	19
4.2 STUDY CHARACTERISTICS.....	24
4.3 RISK OF BIAS IN STUDIES.....	25
4.4 RESULTS OF INDIVIDUAL STUDIES	27
5. DISCUSSION.....	33
6. CONCLUSIONS	40
ACKNOWLEDGEMENTS.....	40
CONFLICTS OF INTEREST	40
7. REFERENCES	41
APPENDIX	55
APPENDIX 1	55
APPENDIX 2	59
APPENDIX 3	75

I. List of signs and acronyms

MS: maxillary sinus

PSAA: posterior superior alveolar artery

CBCT: cone-beam computed tomography

RCT: randomized clinical trial

TSFE: transcrestal sinus floor elevation

EBG: endosinus bone gain

MBL: marginal bone loss

II. ABSTRACT

Objectives: The aim of this study was to determine the differences in endosinus bone gain in height, marginal bone loss, complications, the survival rate and patient satisfaction of the implants placed using transcrestal sinus floor elevation with and without bone graft, with a minimum follow up period of 6 months after surgery.

Materials and methods: An electronic and manual search were conducted to retrieve clinical studies on transcrestal sinus floor elevation with or without graft. The electronic search was performed on three online databases: PubMed/MEDLINE, Scopus, and Web of Science from January 2012 to January 2022, relevant studies were selected according to the inclusion criteria.

Results: 8 articles were selected and a total of 366 implants were studied, of which 228 were placed with a graft biomaterial and 138 without any bone graft biomaterial. Within a follow up from 24 to 120 months the survival rate was 96.7% for the grafted group and 97.2% for the group without graft.

There was no significant difference in endosinus bone gain, marginal bone loss after a period of three years between the grafted and non-grafted implants. The complications found were not related to the insertion or not of a grafting material.

Conclusions: Sinus augmentation via transcrestal access is a safe and predictable technique and its prognostic does not change when bone graft material is not used.

III. Keywords

Transcrestal sinus elevation; indirect sinus floor augmentation; sinus lift with bone graft; graft-less sinus lift; osteotome technique; maxillary sinus; bone regeneration.

1. Introduction

1.1. Sinus lift surgery

Replacing one or more missing teeth with dental implants is a good treatment option with a high success rate (1–3). However, the region of the posterior maxilla is often limited for standard implant placement since the alveolar bone height is substantially reduced because of the presence and pneumatization of the maxillary sinus, and this can lead to a situation where dental implants can not be placed (1,2). As the field of implant dentistry evolved, surgical techniques like the maxillary sinus lift have been developed to allow implant placement in sites like the posterior maxilla, where the alveolar bone is deficient.

The sinus lift surgery is a predictable and successful surgical technique that allows an increase in bone height for cases presenting bone atrophy in the area of the posterior maxilla (1–4), the objective of the surgery is to regenerate the missing bone in order to achieve enough stability to place one or more dental implants. This procedure has also been referred to in the literature as maxillary sinus elevation, maxillary sinus floor augmentation, maxillary sinus floor elevation, sub-antral augmentation.

The maxillary sinus floor elevation technique was first described and published in 1980 by Boyne and James (5). They described a two-stage procedure where in the first stage, the maxillary sinus was augmented with autogenous bone graft harvested from another site and then placed in the maxillary bone through a lateral window. After a healing period, they inserted implants to support a fixed or removable prosthesis (5). Such an approach is relatively invasive, so if the patient has pre surgical adequate bone height a less traumatic transcrestal approach can be adopted to elevate the sinus, which was described by Tantom (6) in 1986.

In 1994 Summers (7) proposed a more conservative approach: the transcrestal technique. He used a set of tapered osteotomes of increasing diameter to elevate the floor of the sinus, this surgical technique is commonly referred to as the “osteotome technique” or “Summers technique”. This approach can be considered less traumatic and more conservative than the lateral window access but can be used only if the patient has adequate bone height.

Nowadays, two main techniques are used to perform this surgery: the lateral approach through a lateral antrostomy, which is the standard technique described by Boyne and James (5), and the transcrestal approach, described by Summers (7).

1.2. Maxillary sinus

A sinus is an empty space within the bone, covered by a layer of mucous membrane. Within the human skull, there are four pairs of paranasal sinuses: the maxillary, ethmoid, frontal, and sphenoid sinuses (8). The paranasal sinuses communicate with the nasal cavity, inside them the inspired air is warmed up and humidified so that optimal exchange of oxygen and carbon dioxide can happen in the lungs (8). Moreover, functions associated with the sinuses include decreasing the physical weight of the bones, providing resonance to achieve a functional phonation, detecting changes in the environmental pressure, providing a shock resistance in case of traumatic injuries, and moderating the airflow in respiration (9,10).

1.2.1. Physiology and histology

The maxillary sinuses (MS) are the largest of the paranasal sinuses, having an average volume of 12,5mL (minimum 5 mL and maximum 22 mL) (11). They are lined by a thin bilateral mucoperiosteal membrane: the side facing the lumen of the sinus is comprised of pseudostratified columnar epithelium with many goblet cells, being supplied by a vascularized lamina propria which contains serous glands, mucous glands, and venules. Whereas the bone side is comprised of an osteogenic periosteal layer (10). The periosteal layer contains stem cells, which have osteogenic potential and it is thought to be important in the healing of bone grafts used in sinus floor elevation treatments to increase in height the edentulous posterior maxillary segments prior to implant insertion (12). This membrane is also called the Schneiderian membrane.

The Schneiderian membrane, defined as the mucoperiosteal layer that lines the MS, is composed of epithelium and a lamina propria which make up the mucosa, and the underlying periosteum (3).

The epithelium lining the sinuses has an important role when the mucous accumulates: the mechanical activity of cilia carries the mucus from the sinuses to the nasal cavity,

then to the nasopharynx, where it is ingested into the gastrointestinal tract. In the maxillary sinus, the mucus is moved toward the sinus ostium in the superior medial wall and subsequently, it is drained into the ethmoidal infundibulum so that the airway is protected against debris, infections, and inhaled irritants (4).

1.2.2. Mucosa

The mucosa is a thin, homogeneous soft tissue that lines the inner walls of MS (8). Most authors consider mucosal thickening higher than 2–3 mm to be pathological, nevertheless normal thickness of the mucosa remains a discussed topic (15,16). The male mucosa is thicker than the female mucosa, and mucosal thickness diminishes from anterior to the posterior area in both sexes (16), apart from that, periapical pathology of teeth or clinical intervention are the most common factors that generate mucosal thickening in the lower portion of the maxillary sinus (15).

1.2.3. Osteology

The maxillary sinus has the shape of a pyramid, with a flat non-pointed apex that is directed towards the zygoma and has its base to the side of the nasal cavity. The posterior and inferior walls are the only thin walls of the sinus, whereas all the other walls are usually thick under normal conditions (4,8).

The maxillary sinus's medial wall is composed of a thin bony plate which is formed by the maxilla, the inferior turbinate, the uncinat process, the palatine bone's perpendicular plate, and the lacrimal bone. Moreover, the MS ostium is located anteromedially and has a diameter of 3 to 4 mm, the uncinat process largely covers its medial aspect (17).

The floor of the MS is composed of the alveolar and palatine process of the maxilla, it is located from 1.0 to 1.2 cm below the floor of the nasal cavity (18) and it extends from the premolar area to the maxillary tuberosity (4). The posterior teeth are separated from the MS by compact bone, which can be insufficient or missing in some cases, allowing the roots of some posterior teeth to protrude inside the MS and eventually make a way for odontogenic infections to spread directly into the sinus.

The roof of the MS is formed by the floor of the orbital cavity. The infraorbital foramen has proximity to the anterior wall of the MS, more precisely in the middle superior part

of it, and the thinnest part of the anterior wall is the canine fossa, while the posterior wall of the MS borders with the pterygomaxillary fossa (17).

1.2.4. Innervation

The MS is innervated by the posterior superior alveolar nerves, which are collateral branches of the maxillary nerve, and by the anterior and middle superior alveolar nerves, which are collateral branches of the infraorbital nerve (17). The MS anterior area is mainly innervated by the middle superior alveolar branch. The nervus intermedius of the facial nerve sends parasympathetic secretomotor fibers to the pterygopalatine ganglion, where they synapse and travel to the sinus mucosa through the trigeminal sensory branches (17).

1.2.5. Blood supply

The MS is irrigated by the posterior superior alveolar artery, the infraorbital artery, and the posterior lateral nasal artery, which are all branches of the maxillary artery (19,20). The posterior superior alveolar artery (PSAA) descends on the maxillary tuberosity and enters the posterior alveolar canals to supply the lining of the MS through the sinus's medial wall. The infraorbital artery extends through the infraorbital groove and canal, under the orbit, and out the infraorbital foramen on the maxilla's facial surface, within the infraorbital canal it gives off the anterior superior alveolar arteries which also supply the maxillary sinus (20).

The PSAA and the infraorbital artery join in an intraosseous anastomose inside the sinus lateral wall and form the alveolar antral artery, guaranteeing hematic contribution to the sinus membrane and the periosteal tissues, especially the anterior lateral wall of the sinus (19). In addition to that, between these two arteries an extraosseous anastomosis is commonly found. The lateral wall of the nasal cavity and paranasal sinuses are supplied by the sphenopalatine artery, which courses through the sphenopalatine foramen giving off posterior lateral nasal arteries (20).

1.2.6. Sinus pneumatization and bone loss in the posterior maxilla

After birth, the maxillary sinuses are continuously expanding, and as patients grow older, the sinus shape changes into an upside-down pyramid. This process is known as sinus pneumatization (21,22).

According to the pneumatization theory of Witmer, pneumatized areas are the result of two opposing forces: one is the epithelium's tendency for opportunistic expansion, while the other is the requirement for a structurally sound and functionally efficient osseous architecture (23).

In view of the fact that maxillary sinuses are subject to pneumatization, intrasinus bony structures like the septa are required throughout development to protect against external physical stresses. Bone deposition would support these, their presence reflects the pattern of epithelial expansion. The constant alternation between bone deposition and epithelial expansion causes several septa variations within the population (23).

Two other theories exist: the first asserts that the degree of pneumatization is genetically determined, and the second claims that the degree of pathogenic involvement throughout childhood determines the level of pneumatization. But also, the pressure generated by the inspired air could influence the process of pneumatization (24).

Furthermore, in the maxilla, posterior teeth extraction or absence can cause alveolar ridge remodeling, which can result in a downward expansion of the maxillary sinus. From a clinical point of view, maxillary sinus pneumatization and ridge resorption in the coronal area of the extraction socket can reduce the available bone height for future implant insertion (25,26).

The first premolar is the tooth which is the farthest away from the maxillary sinus floor, whereas the second molar's mesiobuccal root is the closest. The roots of the maxillary first premolars rarely project into the MS, whereas the palatal root of the first molar is the most typically observed extending into the MS (27,28).

Second upper molar extraction results in the most extensive sinus pneumatization, which should be considered if the patient needs implant rehabilitation (21).

[1.3. Indication for sinus lift surgery.](#)

The general indication for a sinus lift surgery is implant placement in the premolar and/or molar area of the maxilla with inadequate bone height at implant sites (2,3,29).

As described, the loss of alveolar bone in the posterior maxilla is often the result of two processes: firstly, post extractive bone loss and secondly MS pneumatization, which reduces the distance from the sinus to the residual alveolar crest (30). Together or alone, these two processes result in inadequate bone support for implant placement (3). Moreover, the low quality of the residual bone can worsen the implant survival prognosis (31). In fact, to diagnose and treat a patient who needs implant placement in the posterior atrophic maxilla, it is important to understand the quantity and quality of bone left. Only after that, it can be established if to rehabilitate with implants a bone height gain is needed or not.

1.3.1. Classifications of bone loss pattern

The pattern of bone loss after tooth extraction has been classified in different ways. J. L. Cawood and R. A. Howell (32) examined three hundred dried skulls and developed a classification of edentulous jaws aimed to describe the pattern of bone resorption in the various edentulous parts of the jaws simplify the description of the ridge and facilitate communication between clinicians. Image 1 shows the pattern of bone resorption in the posterior maxilla. The classification is the following:

Class I: dentate ridge

Class II: post-extraction alveolar ridge

Class III: alveolar ridge adequate in both width and height

Class IV: knife-edge alveolar ridge shape, adequate height but inadequate width

Class V: flat ridge inadequate in width and height

Class VI: depressed ridge inadequate in width and height (32)

POSTERIOR MAXILLA

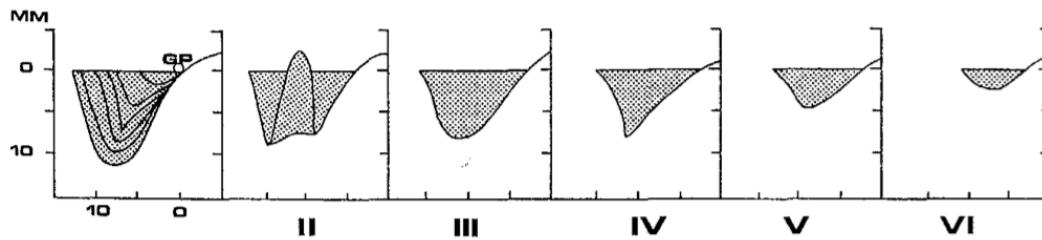


Image 1: Five classes of bone resorption in the posterior maxilla. Class I: dentate ridge. Class II: post-extraction alveolar ridge. Class III: alveolar ridge adequate in both width and height. Class IV: knife-edge alveolar ridge shape, adequate height but inadequate width. Class V: flat ridge inadequate in width and height. Class VI: depressed ridge inadequate in width and height. (32) Cawood JI, Howell RA. A classification of edentulous jaws. *International Journal of Oral Maxillofacial Surgeons*. 1988;17(13):232–6.

However, the resorption of the maxilla should not only be classified regarding bone height and width, but also according to the type of resorption pattern: sinus pneumatization alone, vertical and/or horizontal resorption of the ridge, and the vertical and horizontal relationship between the occlusal plane and the maxillary ridge (33), so Chiapasco et al. (31) developed the following classification of the posterior atrophic maxilla:

Class A: Ridge height between 4 and 8mm. Alveolar width \geq 5mm and absence of significant resorption of the ridge

Class B: Ridge height between 4 and 8mm. Alveolar width $<$ 5mm and absence of significant resorption of the ridge

Class C: Ridge height $<$ 4mm. Alveolar width \geq 5mm and absence of significant resorption of the ridge

Class D: Ridge height $<$ 4mm. Alveolar width $<$ 5mm and absence of significant resorption of the ridge

Class E-H: Same criteria of classes A-D but with significant vertical resorption of the ridge and inadequate vertical intermaxillary relationship

Class I: Severe three-dimensional atrophy of the maxilla, increased crown space vertical dimension, horizontal resorption, and sagittal intermaxillary discrepancy because of centripetal bone resorption of the maxilla (31).

1.4. Pre-operative study

A thorough medical history and physical examination should be performed when planning a sinus lift surgery. Recent upper respiratory infection, acute and/ or chronic sinus disease, chronic sinus/facial pain, otitis media, history of nasal/sinus surgery, antral polyps, cysts or tumors, history of prior attempts at maxillary reconstruction, and history of smoking should be noted. A consultation with an otorhinolaryngologist prior to the surgery is essential in these cases. While there are some relative contraindications for the procedure, there are almost no absolute contraindications, except for patients with decompensated metabolic diseases, patients undergoing chemotherapy and/or radiotherapy, and patients with uncontrolled periodontal disease (3,30).

The distance from the mandibular occlusal plane and the maxillary ridge should be examined, if it measures less than 5 millimeters the prosthetic treatment can be compromised. The relationship between the mandibular occlusal plane and the maxillary ridge should also be determined in the buccolingual dimension so that the future maxillary prosthesis will have its buccal cusps lateral to the buccal cusps of the mandibular antagonist tooth. To better study inter-arch relationships and future occlusion, a diagnostic wax-up can be fabricated and the information obtained can be integrated with a radiographic study (30).

The surgical approach to be used is determined by the class atrophy of the posterior maxilla, the vertical bone height of the residual ridge, location of the maxillary sinus, the thickness of the Schneiderian membrane, the thickness of the lateral wall of the sinus, the presence of sinus septa or sinus pathology, and the antral artery course (30,34). These variable factors must be examined when planning the surgery by using cone-beam computed tomography (CBCT), which is highly essential for the success of the surgery since the clinician can understand whether the surgery is possible or the risk for complications could occur (34).

1.5. Sinus lift surgery, the lateral approach

This technique consists in opening lateral access to the MS through a lateral window and filling part of the sinus with bone graft material to gain bone height. A lateral approach is used when the residual bone is at least 3 to 5 millimeters in height (2,35), in order to provide sufficient primary stability of the implant. This technique has high survival rates that range around 93,7% after 6 years (2), however, the two main complications associated with this technique are the risk of perforation of the Schneiderian membrane while instrumenting during the antrostomy, and the bleeding caused by the injury of the antral artery (36). The risks can be reduced by adopting a less invasive transcresal technique or using piezoelectric instruments. This technique implies delayed rehabilitation.

Preoperative imaging study is a vital factor in the success of the surgery (37), considering that special attention is required to not compromise the alveolar antral artery during osteotomy. Furthermore, to avoid the MS membrane perforation, clinicians should be more careful in the presence of thick lateral walls, presence of septa in the MS, reduced sinus width, and the presence of sinus pathologies. The lateral window should be designed closer to the MS's anterior wall and floor, to have better access for the instrumentation of the membrane and avoid its perforation (30,38).

The surgery is realized first achieving anesthesia by local infiltration and greater palatine and posterior superior alveolar nerve blocks (39). A crestal incision on the alveolar ridge of the posterior maxilla is performed, possibly towards the palatine to ensure enough flap thickness and better healing. Relief incisions may be performed in mesial, distal, or both if needed. A full-thickness mucoperiosteal flap is raised to provide access to the lateral antral wall of the MS (4,39).

The osteotomy is made using a round bur mounted on a high-speed rotatory instrument or piezoelectric instruments, all osteotomies are performed under constant irrigation with physiological serum. The goal is to create a lateral window in the bone and establish communication with the MS and access for instrumentation (4,39).

The Schneiderian membrane, being from white gray to blueish-purple in color, should be visibly exposed once the osteotomy is accomplished, and the middle bony wall should be movable because it would be only attached to the underlying membrane (30). The bony wall can be either pushed in the sinus and then located over the graft material to form a new sinus floor or removed to allow better access to the MS (30,39).

The membrane is gently separated from the bone and elevated with specific curettes starting in order from the above, distal, mesial, and the floor respectively. Once the membrane is elevated and some space to host the bone graft material is created, a cotton or gauze soaked with 2% lidocaine containing epinephrine 1:100,000 can be placed in the space to achieve hemostasis and improve the direct vision of the surgical field (40). At this stage of the surgery, the clinician should check for membrane perforation.

After carefully filling with bone graft material every area of the space created lifting the membrane, the window can be covered using a synthetic membrane. To conclude, the flap is repositioned and sutured correctly, to avoid wound dehiscence and graft contamination (4,30,39). Implants are either placed at the same time of grafting, which would be referred to as 1-stage surgery, and it is performed only when it's possible to have sufficient implant primary stability, or after 12 months since the sinus has been grafted: 2-stage surgery (2,4).

1.6. Sinus lift surgery, the transcrestal approach

This approach consists in performing an osteotomy accessing from the crest of the alveolar ridge, hence this technique is referred to as transcrestal sinus elevation. The osteotomy will allow indirect access to the maxillary sinus and, when compared with the lateral antrostomy, it has the advantage to be not only less invasive and more conservative but also implies lower postoperative morbidity, less time to load the implant, and high survival rates that range around 97,2%. Moreover, most of the time the implants are placed in the same session (2,41).

On the other hand, it is more suitable to use the transcrestal approach when a single tooth needs to be replaced. This technique can only be used when there is enough

vertical bone height in the posterior maxilla, so the residual bone has to be at least 5 to 6 millimeters in height in order to perform this surgical technique, but studies report that this technique is used when the residual bone height is less than 6 millimeters (2,3,39,41–49). This surgery is blinded, because the clinician is not able to directly visualize the sinus membrane, and it can render it more difficult to solve a complication caused by membrane perforation. A predictable outcome is obtained when the MS sinus floor is free of septa and the Schneiderian membrane is kept intact (2).

After local anesthesia is achieved, a crestal incision is performed and a full-thickness flap is lifted to expose the alveolar ridge, nevertheless, a flapless technique can be used (39). A 2 millimeter twist drill is used to remove bone until 1 millimeter from the sinus floor, then the osteotomy is expanded from 0,5 to 1,2 mm less than the implant diameter with sequential osteotomy drills of increasing diameter or a series of osteotomes of increasing diameters tapped with a mallet in order to compress the bone by pushing it laterally and apically, to fracture the floor of the sinus and to elevate the sinus membrane. Before the surgery, the preoperative bone height below the sinus is determined to calculate the desired extension of the drills or the osteotomes inside the bone (3,4,39).

At this point particles of bone graft can be inserted into the osteotomy and moved apically by tapping lightly, fracture of the sinus floor can be detected by noting the change in resistance between the osteotome and the bone or a change in the sound when tapping (39).

However, due to the exceptionally good healing capacity of the chamber created below the Schneiderian membrane (50–52) the need for addition of graft material is questionable. This concept might suggest that a graftless indirect sinus elevation could be a predictable and successful technique (2,46–49,53–71), in addition, it excludes the possible risks of placing graft material inside the sinus and the cost of it.

1.6.1. Different techniques for the crestal approach

- Hydraulic transcresal sinus lift or balloon technique: this variation of the transcresal technique aims to prepare a transalveolar osteotomy using drills and, once the sinus is reached, the membrane is elevated using a hydraulic lifter with light pressure. A tube connects the balloon to a syringe filled with saline solution, when the clinician pressures

the plunger of the syringe, the balloon inflates, and the sinus membrane is elevated (72,73). The hydraulic system minimizes the perforation risk because it distributes the lifting pressure evenly (72), ensuring membrane safety and less post-operative bleeding. This method can be beneficial in hard to access situations when adjacent teeth are present, moreover, blood circulation in the vascular and reticular layers will remain intact, allowing vascularization of augmented tissue (73,74).

- Transcrestal sinus floor elevation using press-fit bone cylinders: first, a cylinder of bone is harvested, then the sinus is reached by opening a transcrestal circular window. The elevation of the sinus floor is performed with a blunt plunger in order to not perforate the membrane. Then the transplant bone cylinder can be implanted with the plunger by mallet strokes after positioning it manually. A clinical advantage of this technique is that the bone graft can not be dislodged into the free sinus space, as it fits perfectly the osteotomy (75,76).

- Hydrodynamic Piezoelectric Internal Sinus Elevation: a piezoelectric instrument is an ultrasonic device used to make osteotomies, reducing the risk of membrane perforation, since it does not cut soft tissues. The piezoelectric surgery systems come with many different inserts, from osteotomes to diamond-cutting inserts, to inserts to help elevate the sinus membrane. A round carbide insert is connected to the ultrasonic piezoelectric device and used to break the floor of the maxillary sinus, then a wider hydrodynamic piezoelectric internal sinus elevation insert is used to enlarge the osteotomy and to lift the sinus membrane through hydrodynamic pressure by internal irrigation concurrently (3,77).

- Osseodensification approach: this method consists in performing the transcrestal osteotomy using burs of increasing diameter with many grooves, the burs are supposed to rotate in an anticlockwise direction. This approach is less traumatic than conventional drilling since it tends to compress the bone instead of eliminating it, in fact, the healing time of the bone is faster and the bone density around the implants is increased. Moreover, an implant with a wider diameter could be placed in a narrow ridge avoiding bone dehiscence or fenestration (78,79).

2. Justification, hypothesis, and objectives

Justification: Implants placed in the posterior atrophic maxilla are often a decisive factor for the overall success of a prosthesis and can be placed using complex surgical procedures like sinus floor augmentation together with the use of a bone graft to gain bone support that the maxilla is lacking. These techniques are associated with higher cost, increased treatment time, and greater morbidity. So, there is a need of rendering these procedures even safer, less invasive, and less expensive for the patient from an economic point of view.

Hypothesis: When indicated, performing a transcrestal sinus lift without bone graft does not show a significant difference regarding endosinus bone gain, marginal bone loss, complications and implant survival when compared with transcrestal sinus lift with bone graft, while still being a valid, successful, and predictable treatment option.

Main Objective:

1. Systematically review the literature concerning the treatment outcome comparison between indirect sinus lift technique with and without graft material in atrophic posterior maxillae.

Secondary objectives:

1. Determine the differences of endosinus bone gain in height and marginal bone loss of the implants placed using transcrestal sinus floor elevation with and without bone graft, with a minimum follow up period of 6 months after surgery.
2. Evaluate the influence of a graft-less transcrestal sinus elevation on post-surgical complications and implant success rate.
3. Evaluate and compare the degree of patient satisfaction after a transcrestal sinus elevation with or without bone graft.

3. Materials and methods

This systematic review was conducted in accordance with the guidelines of the Preferred Reporting of Systematic Reviews and Meta-analyses (PRISMA) statement (80) (Appendix 1) and followed the models proposed in the literature. The protocol of this review was registered in the International Prospective Register for Systematic Reviews (PROSPERO). Clinical questions were separated and organized using the P.I.C.O. strategy (population, intervention, comparisons, outcomes, study design).

3.1. Selection of studies - P.I.C.O. question (Focused question)

The variables of population, intervention, comparison, and outcomes were used to formulate the following question:

Is the indirect sinus lift technique, without the use of bone graft material, a valid technique to treat with implants atrophic posterior maxillae when compared with transcrestal technique with bone graft in the same category of patients?

Population: Patients (> 18 years old) needing implant/s posterior atrophic maxillae.

Intervention: Transcrestal sinus elevation with any technique, without using bone graft.

Comparison: Transcrestal sinus elevation with any technique, using bone graft material.

Outcomes: Primary outcome measures include the amount of bone height gained and peri-implant marginal bone loss. Secondary outcome measures include, survival rate of implants, post-surgical complications and patient's satisfaction.

The inclusion criteria were:

- Prospective and retrospective cohort studies, controlled clinical trials (CCTs), and randomized clinical trials (RCTs) that analyzed the amount of bone formation after indirect maxillary sinus lift with and without the use of bone graft material
- Transcrestal sinus lift without bone graft performed using a well-defined surgical procedure and reporting detailed information
- Minimum follow-up of 6 months after surgery

- Articles reporting implant survival and success rate, alveolar bone gain, crestal bone loss, or post-surgical complications
- Case series with more than 10 cases
- Article in English, Spanish and Italian published during the last 10 years

The exclusion criteria were:

- Systematic reviews, meta-analysis, literature reviews, and letters to the editor
- Case reports
- Animal studies
- Studies on direct sinus lift or comparing between direct and indirect elevation
- Studies involving volunteers with decompensated metabolic diseases
- Studies involving participants aged < 18 years old

3.2. Search strategy and sources of data

Relevant studies were identified through three online databases: PubMed/MEDLINE, Scopus, and Web of Science. All the results had to be published during the last 10 years. The last search was conducted on the 13th of January of 2022 in the three databases mentioned. To complement the databases search, cross-searching of cited references in the studies that were eligible after the full-text screening was performed. A manual search was also carried out in the following international journals: Implant dentistry, International Journal of Implant Dentistry, Journal of Clinical Experimental Dentistry, Journal of Periodontology, Journal of Oral Implantology, Periodontology 2000, and Clinical Oral Implants Research from January 2012 till January 2022.

The following search strategy was used: ("Sinus Floor Augmentation" [Mesh] OR "sinus lift" OR "sinus augmentation" OR "sinus elevation" OR "osteotome technique" OR "sinus graft" OR "sinus floor elevation" OR "sinus floor lift") AND ("indirect" OR "transcrestal" OR "transalveolar" OR "osteotome" OR "bone graft*" OR "graft*" OR "bone augmentation" OR "graft-free" OR "non-graft*") AND ("dental implants")

Database	Search strategy	Filters	Date of search
PubMed/ MEDLINE	("Sinus Floor Augmentation" [Mesh] OR "sinus lift" OR "sinus augmentation" OR "sinus elevation" OR "osteotome technique" OR "sinus graft" OR "sinus floor elevation" OR "sinus floor lift") AND ("indirect" OR "transcrestal" OR "transalveolar" OR "osteotome" OR "bone graft*" OR "graft*" OR "bone augmentation" OR "graft-free" OR "non-graft*") AND ("dental implants")	Published during the last 10 years	13/01/2022
Scopus	("Sinus Floor Augmentation" [Mesh] OR "sinus lift" OR "sinus augmentation" OR "sinus elevation" OR "osteotome technique" OR "sinus graft" OR "sinus floor elevation" OR "sinus floor lift") AND ("indirect" OR "transcrestal" OR "transalveolar" OR "osteotome" OR "bone graft*" OR "graft*" OR "bone augmentation" OR "graft-free" OR "non-graft*") AND ("dental implants")	Published during the last 10 years	13/01/2022
Web of Science	("Sinus Floor Augmentation" [Mesh] OR "sinus lift" OR "sinus augmentation" OR "sinus elevation" OR "osteotome technique" OR "sinus graft" OR "sinus floor elevation" OR "sinus floor lift") AND ("indirect" OR "transcrestal" OR "transalveolar" OR "osteotome" OR "bone graft*" OR "graft*" OR "bone augmentation" OR "graft-free" OR "non-graft*") AND ("dental implants")	Published during the last 10 years	13/01/2022

3.3. Process for the selection of the studies

Titles and abstracts of all the results yielded in the last search were downloaded in the software Mendeley (Mendeley desktop version 1.19.8 © 2008-2020 Mendeley Ltd. All rights reserved) to manage bibliographic references and remove the duplicates.

The individual references were exported to an excel spreadsheet (Microsoft Excel for Mac version 16.59 22031300 © 2022 Microsoft. All rights reserved) with the following information: author's name, date of publication, article title, journal, volume, issue, and abstract. The spreadsheet was used to organize all the studies obtained through the search.

3.4. Screening for article selection

Titles and abstracts of all the references obtained through the last search on the electronic databases were examined independently and blindly by two reviewers (M.N. and A.B.). The two reviewers selected for the analysis of the full text the studies that complied with the inclusion criteria or the ones with insufficient data to make a decisive exclusion. The disagreement regarding inclusion or exclusion was solved through a third reviewer (A.M.P.).

After the initial selection, the same reviewers read independently and blindly the full-text version of the selected articles that could be potentially included in this systematic review. The final selection of articles was made based on the eligibility criteria mentioned above. Cohen's kappa coefficient was calculated to measure inter-examiner agreement.

3.5. Risk of bias assesment

The risk of bias was analyzed by the author (M.N.) for each of the articles selected. The Cochrane Risk of Bias Tool for randomized controlled trials (81) was used, an Excel (Microsoft Excel for Mac version 16.59 22031300 © 2022 Microsoft. All rights reserved) tool to implement RoB 2 was downloaded and it aided to assess the risk of bias for all randomized studies. The ROBINS-I risk of bias tool to assess non-

randomized studies of interventions (82) was used to assess the risk of bias in all non-randomized studies of interventions. The risk of bias according to these tools was classified as low, unclear, or high.

3.6. Data extraction

The data extraction of the selected references was performed by the author (M.N.). An excel spreadsheet (Microsoft Excel for Mac version 16.59 22031300 © 2022 Microsoft. All rights reserved) was used and the following data were identified and extracted: First author, year, type of study, number of patients, age, gender, number at start, number at end, use of bone graft, implant diameter, implant length, number of sinuses elevated, implant site, make of implant, implant number, biomaterial used, preoperative residual bone height, endosinus bone gain, implant protrusion length, follow up, survival rate, marginal bone loss, complications, patient satisfaction, number of patients who smoke.

4. Results

4.1 Study selection

The search yielded a total of 2292 records, of which 704 were from PubMed, 546 from Scopus, and 1042 from Web of Science. The duplicates were removed, and a total of 1184 records were screened by title and abstract. After the screening process, 95 registers were selected for full-text retrieval and assessment according to eligibility criteria. A total of 6 articles met our inclusion criteria (Appendix 3).

The cross-searching of cited references in the studies that were eligible revealed one potential record which was then included in the screening process and later included in this review. The manual search which was carried out in the international journals mentioned previously yielded one record that met our inclusion criteria, and it was included in this review.

A total of 8 articles were included in this systematic review. Cohen's kappa coefficient to measure inter-examiner agreement was calculated ($K= 0.91$) and it indicated an almost perfect agreement between the reviewers for the analysis of the full text. Image 2 represents this process using the PRISMA flow diagram (80).

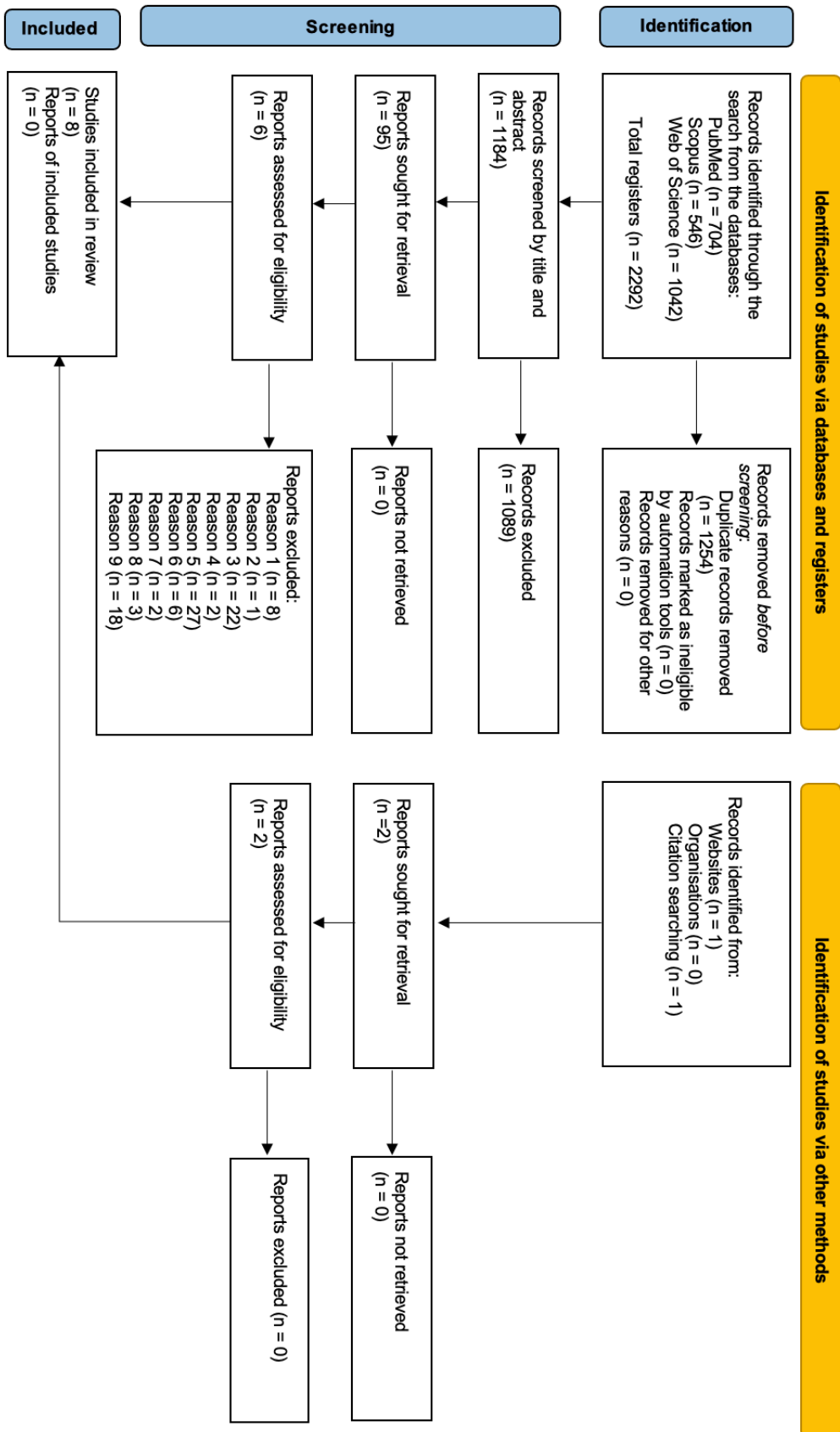


Image 2: Flow diagram of the systematic review using the PRISMA flow diagram (80). Page MJ, McKenzie JE, Bossuyt PM, Boutron I, Hoffmann TC, Mulrow CD, et al. The PRISMA 2020 statement: an updated guideline for reporting systematic reviews. *BMJ*. 2021 Mar;372:n71.

Table 1 depicts the reasons for the exclusion of each article after reading the full text

Authors and year	Criteria
Zahedpasha et al. 2021 (83)	1
Borges et al. 2011 (84)	1
Cricchio et al. 2011 (85)	1
Riben et al. 2016 (86)	1
Tomruk et al. 2016 (87)	2
Malchiodi et al. 2016 (88)	3
Lombardo et al. 2020 (89)	3
Soydan et al. 2015 (90)	1
Lumbau et al. 2021 (91)	3
Freiha et al. 2021 (92)	3
Pabst et al. 2015 (93)	3
Mandelli et al. 2013 (94)	4
Zhen et al. 2012 (95)	3
Bensaha 2012 (96)	3
Bernardello et al. 2011 (97)	3
Baldi et al. 2011 (98)	3
Mazor et al. 2011 (99)	3
Nizam et al. 2020 (100)	3
Shi et al. 2020 (101)	5
Rammelsberg et al. 2020 (45)	5
Shi et al. 2019 (102)	3
Nahlieli et al. 2019 (103)	5
Wang et al. 2019 (104)	6
Zill et al. 2016 (105)	5
Nedir et al. 2016 (58)	5
Magdy et al. 2021 (106)	3
Shi et al. 2021 (107)	5
Volpe et al. 2013 (59)	5

Kakar et al. 2021 (108)	7
Gai et al. 2021 (109)	5
Li et al. 2020 (110)	5
Brizuela et al. 2014 (60)	5
Shi et al. 2015 (111)	3
Bae et al. 2015 (112)	8
He et al. 2013 (113)	5
El Hage et al. 2019 (62)	5
Crespi et al. 2012 (114)	5
Caban et al. 2017 (63)	5
Santagata et al. 2012 (115)	3
Xiao et al. 2011 (116)	5
French et al. 2016 (64)	5
Galindo-Moreno et al. 2014 (117)	5
Chandra et al. 2018 (118)	7
Gonzalez et al. 2014 (43)	8
Stefanski et al. 2017 (119)	1
Bruschi et al. 2013 (120)	8
Senyilmaz et al. 2011 (121)	5
Rammelsberg et al. 2015 (65)	9
Kim et al. 2012 (122)	5
Cricchio et al. 2014 (66)	1
Yang et al. 2021 (123)	6
Altintas et al. 2013 (124)	1
Thoma et al. 2015 (125)	9
Zhang et al. 2013 (126)	9
Jiang et al. 2017 (127)	6
Shayesteh et al. 2013 (128)	9
Zhang et al. 2017 (129)	5
Rammelsberg et al. 2012 (130)	5
Sahrmann et al. 2016 (131)	9

Si et al. 2016 (68)	5
Abi Najm et al. 2018 (69)	5
Andrés-García et al. 2021 (47)	5
Fermergård et al. 2012 (70)	5
Lopez-Quiles et al. 2018 (74)	3
Bruckmoser et al. 2018 (132)	9
Xiao et al. 2011 (133)	6
Crespi et al. 2021 (134)	9
Chen et al. 2017 (135)	9
Ahn et al. 2012 (136)	9
Wang et al. 2018 (137)	6
Rammelsberg et al. 2020 (71)	5
Fugazzotto 2017 (138)	9
Lin et al. 2014 (139)	6
Bruschi et al. 2012 (48)	5
Thomas et al. 2018 (44)	4
French et al. 2015 (140)	9
Pozzi et al. 2014 (141)	9
Bruschi et al. 2021 (142)	9
Jain et al. 2021 (143)	9
Mahesh et al. 2019 (144)	9
Gu et al. 2016 (57)	9
Carelli et al. 2021 (145)	9
Volpe et al. 2016 (51)	9
Gatti et al. 2018 (146)	5
Nedir et al. 2016 (147)	5
Nedir et al. 2018 (148)	5
Al Qabbani 2020 (149)	5
Zhao et al. 2018 (150)	5

Table 1 Articles excluded and criteria: 1 (Lateral approach), 2 (Review), 3 (Different objective, no comparison), 4 (Case report having less than 10 cases), 5 (No comparison, only graftless technique), 6 (Article in chinese), 7 (No comparison, only graft technique), 8 (Different objective, not specific results), 9 (Different objective).

4.2 Study characteristics

Six Randomized clinical trials (RCT) (151–156) and two non-randomized studies of intervention (157,158) were included (Table 3). The studies investigated the endosinus bone gain (EBG) (151–158), the marginal bone loss (MBL) (151–154,157), survival rate (151–154,156,157), complications (151–157) and patient satisfaction (152) for the surgeries with and without bone graft.

This systematic review gathered the data of 207 patients, with an age range from 18 to 74 years, who underwent transcrestal sinus floor elevation (TSFE) with or without bone graft. In three studies (151,153,156) some patients suffered perforation of the Schneiderian membrane, and they were excluded from the studies. A total of 366 implants were studied, of which 228 were placed with a graft biomaterial and 138 without any bone graft biomaterial.

The biomaterials used were deproteinized bovine bone (Bio-Oss[®]) mixed with autogenous bone (151,153), deproteinized bovine bone (Bio-Oss[®]) alone (152,154,156–158), acemann extraction and sponge preparation (155), β -tricalcium phosphate (Bone ceramic[®]) mixed with deproteinized bovine bone (Bio-Oss[®]) (156), β -tricalcium phosphate (Bone ceramic[®]) alone (156).

The make of the implants placed were Straumann[®](151–154,156), Biomet 3i[®] (157), Bicon[®] (158), and Osstem Implant[®] (155). Three studies reported the inclusion of smokers who smoke less than 10 cigarettes per day (151,153,155), the rest did not report the smoking status of the patients (152,154,156–158).

4.3 Risk of bias in studies

RCTs: Three (151,153) out of the six RCTs were considered as low overall risk of bias. The randomization process was well defined in all the studies, but in some (152,154,156), the bias due to deviations from intended interventions raised some concerns as it was not mentioned whether if the patients were aware of the treatment option that they received, and for two studies (152,154) the person delivering the intervention was the same that analyzed the outcomes, this might suppose that the carer delivering the intervention was aware of participants' assigned intervention during the trial. Bias due to missing outcome data, measurement of the outcome and selection of the reported result were low for all the studies (Image 3 and 4).

	D1	D2	D3	D4	D5	Overall	
Si et al. (151)	+	+	+	+	+	+	+
Quian et al. (153)	+	+	+	+	+	+	!
Nedir et al. (154)	+	!	+	+	+	!	-
Nedir et al. (152)	+	!	+	+	+	!	
Trinh et al. (155)	+	+	+	+	+	+	
Markovic et al. (156)	+	!	+	+	+	!	

D1	Randomisation process
D2	Deviations from the intended interventions
D3	Missing outcome data
D4	Measurement of the outcome
D5	Selection of the reported result

Image 3: Risk of bias assessment using Cochrane bias tool for RCTs

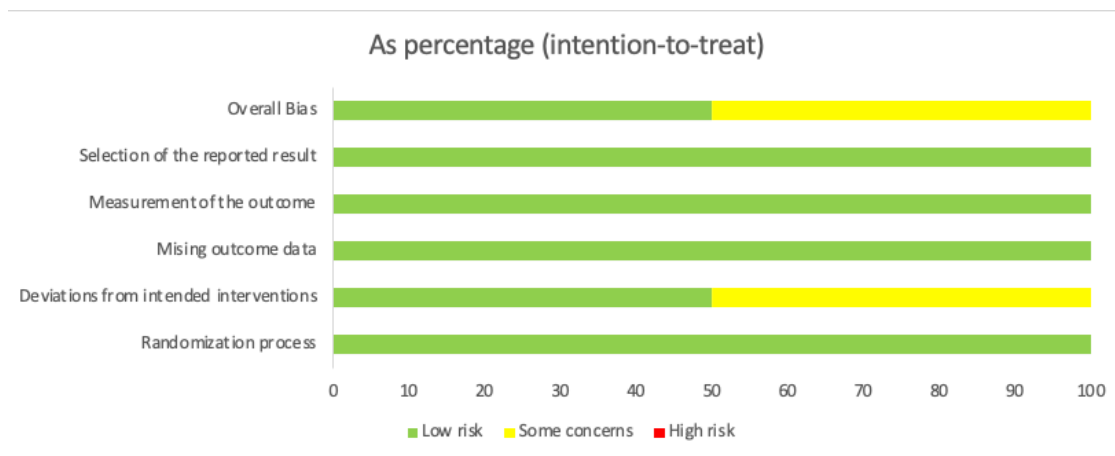


Image 4: summary in percentage of the risk of bias using the Cochrane bias tool for RCTs

Non-Randomized studies: Both studies (157,158) raised some concerns for bias in measurement of outcomes, as one (157) did not mention the grade of knowledge about the intervention received by the patients, and the other one (158) did not mention whether if the assessors were aware or not of the intervention received by participants. Additionally, one (157) raised some concerns for bias due to confounding, because even if the residual bone heights were not significantly different between the two groups of the study, one group (graftless group) received more short implants than the other one (Image 5 and 6).

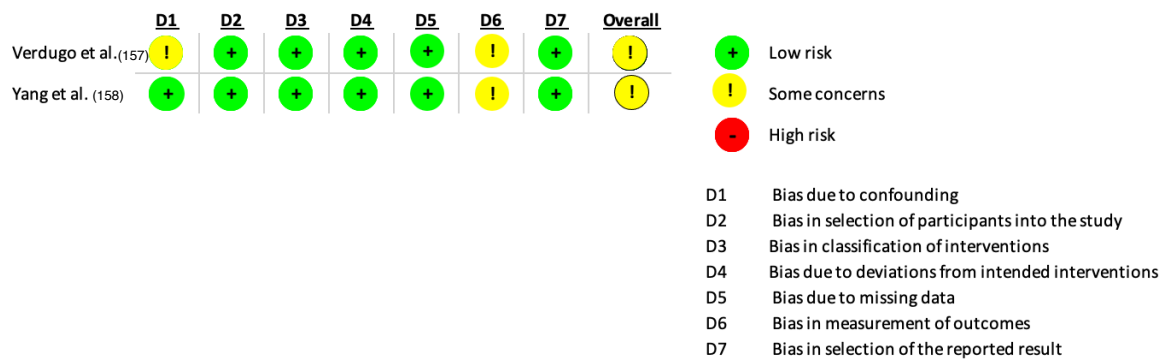


Image 5: Risk of bias assessment using Cochrane bias tool ROBINS-I

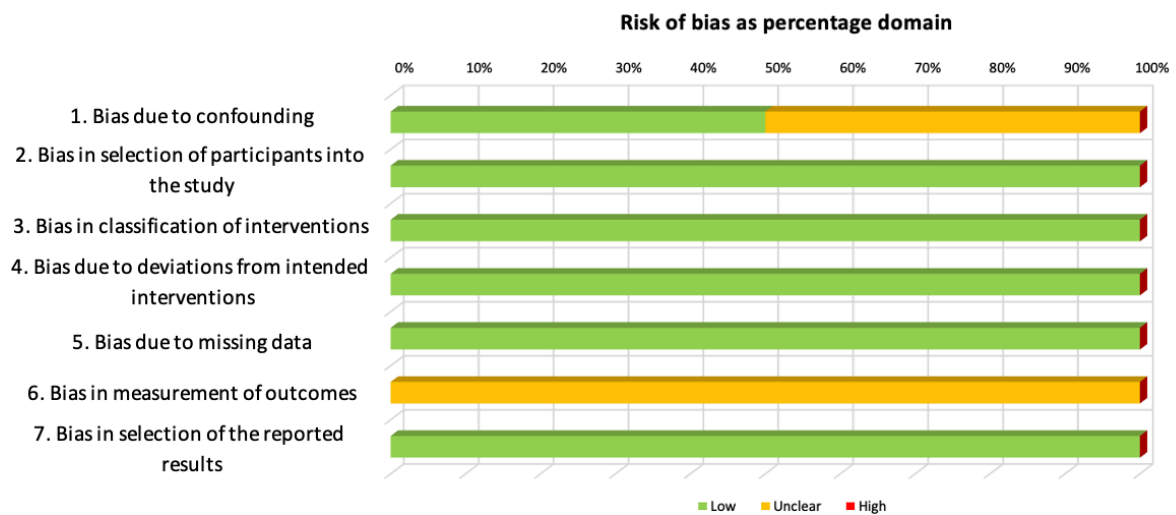


Image 6: summary in percentage of the risk of bias using the Cochrane bias tool ROBINS-I

4.4 Results of individual studies

Si et al. (151) and Qian et al. (153) conducted a randomized controlled clinical trial analyzing the same sample of patients and compared transcrestal sinus floor elevation (TSFE) with and without bone graft, but at different follow up times: minimum 6 months and maximum 120 months. They divided the patients in two groups, one group of 21 patients received TSFE augmented with deproteinized bovine bone (Bio-Oss[®]) mixed with autogenous bone (if present), and the other group of 20 patients without bone graft. Implant length and diameter, which ranged between 6 mm and 10 mm, and 4.1 mm to 4.8 mm respectively, were not significantly different between the two groups. The outcome data was statistically analyzed. The baseline measurements of the residual bone height of both groups did not have a statistically significant difference, and the mean intrasinus implant protrusion length was similar for both groups. The mean endosinus bone gain was significantly higher in the graft group during the first two years, and after resulted in more similar values, but still being higher in the graft group. The marginal bone loss was higher in the group without graft during the year, and the survival rate was adequate in both groups. One 10 mm implant in the graft group and one 8 mm implant in the graftless group were lost at 6-12 months follow up due to periimplantitis and an 8 mm implant in the graft group failed after 6 years of functional loading due to marginal bone loss. The survival rate at 36 months was 95.2% in the graft group and 95.0% in the graftless group. At 120 months 90.7% in the graft group and 95.0% in the graftless group.

Nedir et al. 2013 (154) and Nedir et al. 2017 (152) compared the same sample of 12 patients and investigated TSFE with and without bone graft, all implants were 8 mm long, but at different follow up times: minimum 12 months and maximum 60 months. The control group received 20 implants together with TSFE augmented with deproteinized bovine bone (Bio-Oss[®]) and the test group 17 implants with graftless TSFE. The average residual bone height at baseline was similar between the two groups. The mean endosinus bone gain was significantly higher in the control group, and the marginal bone loss was slightly minor in the control group compared to the test group. Nedir et al. 2017 (152) presented a statistical analysis of the outcome data. A statistically significant difference in mean endosinus bone gain between test and control group was

found at 12, 36 and 60 months, being higher in the control group. However, they obtained relatively high results in terms of EBG in both groups of patients and noted more bone formation in the interproximal surfaces between adjacent implants. The survival rate was high and similar in both groups. At 1.8 months, 2 implants in the control group were mobile and appeared moved coronally, after removal, only one was later replaced without more graft, while at 32.4 months one implant in the test group failed due to peri-implantitis. The study (152) reported complete patient satisfaction at 60 months follow up in all patients of both groups. The survival rate at 12 months was 90% in the graft group and 100% in the graftless group. And at 60 months 90% in the graft group and 91.1% in the graftless group.

Trihn et al. (155) studied a total of 30 patients divided into two randomized groups and underwent TSFE with and without bone graft, the biomaterial used in the graft group was an acemann sponge and the follow ups for both groups were 6 months. Their data was statistically analyzed. There was no statistically significant difference in baseline mean bone height between the two groups, and 11.5 mm long implants were placed in both groups. In the immediate postoperative, the mean bone height of the blood clot was almost identical for the two groups, however at 6 months the grafted group had significantly higher endosinus bone gain. No complications were reported in any group. The survival rate was not reported.

Marković et al. (156) evaluated stability, success rate and endosinus bone gain for 45 patients who received TSFE in 4 sites augmented with either β -tricalcium phosphate (Bone ceramic®) alone, deproteinized bovine bone (Bio-Oss®) alone, β -tricalcium phosphate (Bone ceramic®) mixed with deproteinized bovine bone (Bio-Oss®) or without any bone graft, depending on random assignment. The outcome data of this study was statistically analyzed. The mean preoperative bone height was comparable in all sites, the implants placed measured 10 mm and the mean follow up was 29.7 months. Two examiners who analyzed the endosinus bone gain, had a strong agreement. After 6 months all test groups showed new endosinus bone that covered the implant at least to the apex. All groups showed significant shrinkage of bone volume, after 24 months deproteinized bovine bone (Bio-Oss®) alone showed the most shrinkage (66.34%), β -tricalcium phosphate (Bone ceramic®) mixed with deproteinized bovine bone (Bio-Oss®)

group had the least shrinkage (33.47%), while β -tricalcium phosphate (Bone ceramic®) alone had 61.44% bone loss and the graftless group 53.02%. The two-year implant success rate was 100% in all groups, without any major complications.

Verdugo et al. (157) and Yang et al. (158) conducted non-randomized studies and evaluated the TSFE with and without bone graft and its relation to the endosinus bone gain. The biomaterial used in both studies was deproteinized bovine bone (Bio-Oss®) alone. The first author (157) measured the marginal bone loss and survival rate as well, on 27 patients, at an average of 64.6 months. The baseline mean residual bone height difference between the two groups was not statistically significant, however the mean endosinus bone gain was significantly different, being higher in the graft group, but the marginal bone loss was similar in both groups. All implants had a success rate of 100% at an average of 64.4 months. The second author (158) conducted a retrospective study on 40 patients who received TSFE with and without bone graft using short implants of 6 mm and 8 mm, with a follow up of 18 months. The endosinus bone gain was significantly higher in the graft group at all follow ups (immediate postoperative, 6 months, 12 months and 18 months), partial correlation analysis indicated moderately significant correlation between endosinus bone gain and intrasinus implant protrusion length, being the last one higher in the graft group. The survival rate was not reported.

Table 2: reporting weighted averages of EBG and MBL

The weighted average of the endosinus bone gain (Autogenous + Bio-Oss® GRAFT) (mm)	The weighted average of the endosinus bone gain (Bio-Oss® GRAFT) (mm)	The weighted average of the endosinus bone gain (NO GRAFT) (mm)
5.66 at 6 months (151,153)	4.28 at 6 months (158)	1.64 at 6 months (151,155,158)
3.56 at 12 months (151,153)	4.48 at 12 months (154,158)	2.36 at 12 months (151-154,158)
3.03 at 60 months (151,153)	6.54 at 60 months (152,157)	4.39 at 60 months (152,153,157)
The weighted average of the marginal bone loss (Autogenous + Bio-Oss® GRAFT) (mm)	The weighted average of the marginal bone loss (Bio-Oss® GRAFT) (mm)	The weighted average of the marginal bone loss (NO GRAFT) (mm)
0.44 at 12 months (151,153)	0.4 at 12 months (152,154)	0.96 at 12 months (151,154)
1.33 at 36 months (151,153)	0.5 at 36 months (152)	1.03 at 36 months (151,152)
1.50 at 60 months (151,153)	0.74 at 60 months (152,157)	1.00 at 60 months (152,153,157)

Author	Year	Type of study	Patients	Age range	Gender	N° at start	N° at end	Use of Graft Yes:1 No:0	Smokers
Si et al. (151)	2013	RCT	45	18-35:4 34-55:20 ≥56:17	Male:26 Female:15	45	41	1 0	8 10
Quian et al. (152)	2020	RCT	45	NR	NR	45	40	1 0	8 9
Verdugo et al. (157)	2017	Clinical retrospective	30	64.5 ± 9.5	Males:10 Females:20	30	27	1 0	NR NR
Nedir et al. (154)	2013	RCT	12	57.6 ± 4.7 years	Males:3 Females:9	12	12	1 0	NR NR
Nedir et al. (152)	2017	Prospective RCT	12	57.6 ± 4.7 years	Males:3 Females:9	12	12	1 0	NR NR
Yang et al. (158)	2018	Retrospective study	40	50.6 ± 12.93 years	Males:21 Females:19	40	40	1 0	NR NR
Trinh et al. (155)	2019	RCT	30	51 ± 7 years	Males:10 Females:20	30	29	1 0	NR NR
Markovic et al. (156)	2016	RCT	50	56.7 (mean)	Males:16 Females:29	50	45	1 1 1 0	NR NR NR NR

Table 3: demographic information about the studies included. NR: not reported

Table 4: information about materials used. NR: not reported

Author	Use of Graft Yes: 1 No: 0	Implant diameter					Implant length					Number of sinuses elevated	Implant site		Make of Implants	Number of implants	Biomaterial used
		4.1 mm	4.5 mm	4.8 mm	5 mm	6 mm	8 mm	10 mm	11.5 mm	Premolar	Molar						
Si et al. (151)	1	11	-	10	-	3	8	10	-	NR	7	14	Straumann®	21	Autogenous bone mixed with Bio-Oss®		
	0	8	-	12	-	2	9	9	-	NR	9	11	Straumann®	20	None		
Quian et al. (152)	1	NR	NR	NR	NR	3	8	10	-	21	7	14	Straumann®	21	Autogenous bone mixed with Bio-Oss®		
	0	NR	NR	NR	NR	2	8	9	-	19	9	11	Straumann®	19	None		
Verdugo et al. (157)	1	9	-	7	-	-	2	8	6	NR	7	9	Biomet 3i®- Osseotite®	16	Bio-Oss®		
	0	5	-	9	-	-	7	4	3	NR	4	10	Osseotite®	14	None		
Nedir et al. (154)	1	NR	NR	NR	NR	-	20	-	-	10	5	32	Straumann®	18	Bio-Oss®		
	0	NR	NR	NR	NR	-	17	-	-	9	5	32	Straumann®	17	None		
Nedir et al. (152)	1	NR	-	NR	-	-	20	-	-	10	5	32	Straumann®	18	Bio-Oss®		
	0	NR	-	NR	-	-	17	-	-	9	5	32	Straumann®	16	None		
Yang et al. (158)	1	-	-	-	31	45	6	-	-	NR	NR	NR	Bicon®	24	Bio-Oss®		
	0	-	20	-	-	-	-	-	-	NR	NR	NR	Bicon®	27	None		
Trinh et al. (155)	1	-	-	-	-	-	-	-	14	NR	NR	NR	Ostem Implant®	14	50 mg Acemann® sponge		
	0	-	-	-	-	-	-	-	15	NR	NR	NR	Ostem Implant®	15	None		
Marković et al. (156)	1	-	-	-	-	-	-	-	-	NR	NR	NR	Straumann®	45	BoneCeramic®		
	1	180	-	-	-	-	-	-	-	NR	NR	NR	Straumann®	45	Bio-Oss®		
	0	-	-	-	-	-	-	-	-	NR	NR	NR	BoneCeramic® + Bio-Oss®	45	None		

Table 5: information about EBG, implant protrusion lenght, follow up and survival rate. NR: not reported

Author	Use of Graft Yes: 1 No: 0	Pre-operative residual bone height (mm)	Endosinus bone gain (mm) ($\pm 7m$)										Implant protrusion lenght	Follow up total	Survival rate
			Post- operative	6 m	12 m	18 m	24 m	36 m	60 m	120 m					
Siet al. (151)	1	4.67 \pm 1.18	-	5.66 \pm 0.99	3.56 \pm 1.82	-	3.02 \pm 0.48	3.17 \pm 1.95	-	-	-	-	3.75 \pm 1.43	6-12-24-36 months	95.2%
	0	4.58 \pm 1.47	-	2.06 \pm 1.01	2.45 \pm 0.98	-	3.12 \pm 0.70	3.07 \pm 1.68	-	-	-	-	3.94 \pm 1.63		
Quian et al. (152)	1	4.67 \pm 1.18	-	-	3.56 \pm 1.82	-	-	3.17 \pm 1.95	3.03 \pm 1.61	3.07 \pm 1.34	3.75 \pm 1.43	12-36-60- 120 months	90.7%		
	0	4.58 \pm 1.47	-	-	2.45 \pm 0.98	-	-	3.07 \pm 1.68	3.12 \pm 1.31	3.14 \pm 1.26	3.94 \pm 1.63				
Verdugo et al. (157)	1	3.8 \pm 1.2	-	-	-	-	-	-	8.5 \pm 1.9	-	-	NR	64.6 months	100%	
	0	4.5 \pm 0.8	-	-	-	-	-	-	6.8 \pm 0.5	-	-	NR			
Nedir et al. (154)	1	2.2 \pm 0.8	-	-	5.0 \pm 1.3	-	-	-	-	-	-	-	12 months	90%	
	0	2.6 \pm 0.9	-	-	3.9 \pm 1.0	-	-	-	-	-	-	5.0 \pm 1.2			
Nedir et al. (152)	1	2.2 \pm 0.8	-	-	5.0 \pm 1.3	-	-	-	5.1 \pm 1.2	4.8 \pm 1.2	-	-	60 months	90.0%	
	0	2.6 \pm 0.9	-	-	3.9 \pm 1.0	-	-	-	4.1 \pm 1.0	3.8 \pm 1.0	-	-			5.0 \pm 1.2
Yang et al. (158)	1	NR	4.63 \pm 2.35	4.28 \pm 2.37	4.09 \pm 2.38	3.96 \pm 2.38	-	-	-	-	-	1.80 \pm 1.37	18 months	NR	
	0	NR	1.24 \pm 1.80	1.36 \pm 1.37	1.33 \pm 1.22	1.29 \pm 1.07	-	-	-	-	-	1.26 \pm 0.77			
Trinh et al. (155)	1	NR	6.7 \pm 0.3	3.2 \pm 0.3	-	-	-	-	-	-	-	-	6 months	NR	
	0	NR	6.7 \pm 0.2	1.6 \pm 0.3	-	-	-	-	-	-	-	-			
Markovic et al. (156)	1	6.59 \pm 0.45	-	0.34 cc	0.19 cc	-	-	0.12 cc	-	-	-	-	24 months	100%	
	1	(overall mean)	-	0.34 cc	0.29 cc	-	-	0.24 cc	-	-	-	-			
	0		-	0.43 cc	0.29 cc	-	-	0.22 cc	-	-	-	-		100%	

Table 6: information about MBL, complications and patient satisfaction. NR: not reported

Author	Use of Graft Yes: 1 No: 0	Pre-operative residual bone height (mm)	Marginal bone loss (mm) (±7m)							Complications	Patient's satisfaction
			6 m	12 m	24 m	36 m	60 m	120 m			
Si et al. (151)	1	4.67 ± 1.18	0.21 ± 0.23	0.44 ± 0.16	0.65 ± 0.30	1.33 ± 0.46	–	–	One implant in both groups was lost after 6–12 m. of functional loading, due to peri-implantitis	NR	
	0	4.58 ± 1.47	0.67 ± 0.98	1.28 ± 0.05	1.32 ± 0.45	1.38 ± 0.23	–	–		NR	
Quilan et al. (152)	1	4.67 ± 1.18	–	0.44 ± 0.16	–	1.33 ± 0.46	1.50 ± 0.96	1.67 ± 1.06	One 10 mm imp. failed after 6–12 m. follow-up. Another 8- mm imp. was lost after 6 y. loading due to marginal bone loss	NR	
	0	4.58 ± 1.47	–	1.28 ± 0.05	–	1.38 ± 0.23	1.43 ± 0.76	1.52 ± 1.08		NR	
Verdugo et al. (157)	1	3.8 ± 1.2	–	–	–	–	0.8 ± 0.7	–	Two implants developed 6 mm pockets	NR	
	0	4.5 ± 0.8	–	–	–	–	0.9 ± 0.6	–		NR	
Nedir et al. (154)	1	2.2 ± 0.8	–	0.4 ± 0.7	–	–	–	–	At 1.8 months, 2 impl. were mobile, appeared moved coronally, after removal, only one was later replaced w/o more graft	NR	
	0	2.6 ± 0.9	–	0.6 ± 0.8	–	–	–	–		NR	
Nedir et al. (152)	1	2.2 ± 0.8	–	0.4 ± 0.7	–	0.5 ± 1.0	0.7 ± 1.4	–	At 32.4 months one implant failed due to peri-implantitis	Complete satisfaction	
	0	2.6 ± 0.9	–	0.6 ± 0.8	–	0.6 ± 1.1	0.6 ± 0.9	–		Complete satisfaction	
Yang et al. (158)	1	NR	NR	NR	NR	NR	NR	NR	NR	NR	
	0	NR	NR	NR	NR	NR	NR	NR		NR	
Trinh et al. (155)	1	NR	NR	NR	NR	NR	NR	NR	None	NR	
	0	NR	NR	NR	NR	NR	NR	NR		NR	
Markovic et al. (156)	1	6.59 ± 0.45 (overall mean)	NR	NR	NR	NR	NR	NR	Sinus membrane perforation in 5 patients that were excluded from the study	NR	
	1		NR	NR	NR	NR	NR	NR			
	0		NR	NR	NR	NR	NR	NR		NR	

5. DISCUSSION

The main purpose of this study was to systematically investigate the literature regarding TSFE with or without bone graft in posterior atrophic maxillae and compare the outcomes such as survival rate, endosinus bone gain, marginal bone loss, complications and patient satisfaction. This systematic review included 8 studies: 6 Randomized clinical trials (RCT) (151–156) and 2 non-randomized studies of intervention (157,158). Data was gathered about 366 implants, of which 228 were placed with a graft biomaterial and 138 without any bone graft biomaterial. The follow up of the studies ranged from the immediate postoperative to 120 months. Five articles (151–154) in this systematic review used the implant success criteria by Buser et al. (159) and Cochran et al. (160), two articles (155,158) did not report success rate, and another one used the implant success criteria by Karoussis (161).

The sites that received 228 implants together with bone grafts, had a residual bone height that ranged from 1.4 mm to 7.04 mm, the diameter of the implants placed ranged from 4.1 mm to 5 mm and their length from 6 mm to 11.5 mm. The highest success rate was 100% and the lowest 90%. The most common complications reported were periimplantitis (151,153), and mobility, which was reported in one article (154) and failure due to marginal bone loss (153). One implant out of 228 failed due to periimplantitis at 6-12 months follow up, one due to mobility at 1.8 months, and one due to marginal bone loss. The weighted average of preoperative residual bone heights of all studies except two (155,158) was 5.72 mm. The weighted average (based on graft type) of the endosinus bone gain and marginal bone loss is reported in table 2.

The sites that did not receive any type of bone graft material had ridges of residual bone heights that ranged from 1.7 mm to 7.04 mm, the diameter of the 138 implants ranged between 4,1 mm and 5 mm, and their length between 6 mm and 11.5 mm. The success rate ranged from 94.1% to 100% and the most reported complication was periimplantitis. The most common complication was periimplantitis (152,153). Two implants out of 138 were lost due to periimplantitis, one at 6-12 months follow up and another one at 32.4 months. The weighted average of preoperative residual bone

heights of all studies except two (155,158) was 5,15 mm. The weighted average (based on graft type) of the endosinus bone gain and marginal bone loss is reported in table 2.

Notably, the studies showed no significant difference or advantage between the implants placed with or without bone graft, confirmed by the fact that the survival rate was similar between the two groups: within a follow up from 24 to 120 months the survival rate was 96.7% for the grafted group and 97.2% for the group without graft. However, a difference existed when comparing the endosinus bone gain, resulting slightly higher in the graft groups in the first 3 years, after 3 years the EBG measures tended to similar values in both groups. The marginal bone loss resulted in similar values in both groups. The degree of patient satisfaction could not be assessed, as only one study reported it (152). In other words, the overall results showed concordance over changes of the variables analyzed. However, even if some variables in different studies had higher or lower values when compared to the overall mean, or were registered in different units of measure, they still did show concordance in proportion. Three implants failed in the groups with bone graft and two in the groups without bone graft, but the use or not of the grafting material had no significant influence on the prognosis of the implants. The hypothesis of the study was validated.

The weighted average of EBG and MBL of autogenous + Bio-Oss® shows an important difference if compared to the Bio-Oss® alone, probably because a smaller sample was analyzed, as only one study (151,153) used the mix and the pool of patients that received Bio-Oss® was almost double the amount. Moreover, the Bio-Oss® group values were obtained from a mean between 3 studies (152,157,158). Interestingly the weighted average of the endosinus bone gain at 60 months for the group augmented with Bio-Oss® resulted in higher values when compared at 6 and 12 months, this can be explained because one study reported a mean of EBG at 60 months and used longer implants in comparison to the other studies.

Risk of bias in the studies: One of the main limitations for the studies was a smaller sample of patients and implants analyzed, Nedir et al. (152,154), Si et al., Quian et al. (153) and Verdugo et al. (157) had smaller samples of patients and implants analyzed, this could have slightly altered the outcomes analyzed at some point of the studies. Additionally in the studies conducted by Nedir et al. (152,154) the surgeon was the same

person who registered the results. Surprisingly all the studies reported that the allocation sequence was concealed until participants were enrolled and assigned to interventions, yet three studies did not report whether if the patients were aware or not of the intervention received (152,154,156). An interesting possible cause of bias was found in the study conducted by Verdugo et al. (157) since the number of short implants placed in the graftless group was slightly higher than that of the graft group, possibly altering the outcome of the study. Also, the same author did not mention the grade of knowledge of the intervention received by the person who measured the outcomes (157).

This review reported that a significant factor which influences new bone formation inside the sinus, and therefore enhances EBG, is the extension in which the implants protrude inside the sinus. This factor alone, if an adequate primary stability is achieved, can enhance the formation of new bone, possibly because of the tenting effect. This effect is the result of the elevation of the Schneiderian membrane, which is sustained by the apex of the implant protruding inside the sinus, the more the implant protrudes, the more its apex can act as a stable scaffold that elevates the membrane. Dragonas et al. (162) conducted a systematic review to analyze the potential of osteogenicity of the sinus membrane and concluded that the membrane contains pluripotent mesenchymal cells capable of differentiation and apport new bone formation, such findings reinforce the theory of periosteal-guided bone regeneration, which should not be underestimated or overlooked if there is the need to perform a successful and minimally invasive TSFE, since the tent formed by the membrane is stable and capable of maintaining space for the basic osteointegration process: inflammation of the wound, generation of an oxidized layer on the implant, proliferation and differentiation of the pluripotent stem cells, which are apported by the membrane, and finally osteogenesis and maturation. Moreover, a relevant finding that confirmed a strong correlation between the tenting effect and EBG was published by Song et al. (163) who placed 49 implants without bone graft in atrophic maxillae and studied the tenting effect obtained by lifting the membrane and placing an implant to sustain it. New bone formation was a constant finding at all sites after 6 months, and the amount of bone formation increased proportionally to the length of the implants in the sinus.

This review showed that not only the new bone formation occurred in both groups in the short term, but also that after approximately three years the patients that received bone grafts reported a similar EBG compared to the patients that did not receive any graft, without any change regarding implant success. This is in line with the findings in the literature, as Kim et al. (164) investigated the resorption of different bone grafts in the maxillary sinus 3 years after implant placement and found no difference in shrinkage due to resorption between graft or technique used, meaning that graft materials undergo inevitable shrinkage, eventually stabilize and reach similar dimensions as graftless placed implants.

Another outcome of interest for this review was the marginal bone loss, which was found to be similar in both groups after a three-year period at every follow up. Mainly the most MBL found in patients was associated to periodontitis and not to the grafting technique which was used. In concordance with these results, Fermergård et al. (165) conducted a three-year retrospective study on 53 implants placed using TSFE without bone graft in 36 patients and found that the marginal bone loss had not changed significantly after three years, this is concordant to the outcome of this review, moreover they also found predictable results in terms of clinical success, comparable to grafted implants.

No complications were related to the insertion or not of bone graft in the sinus. Furthermore, the survival rate was not influenced by the grafting technique used. Logically the complications most frequently related to a lower success rate of implants were periodontitis, as some patients in the studies were ex-periodontal patients and mobility due to the lack of primary stability, since the review pooled a significant number of extremely atrophic sites, but no relevant complication appeared because of the grafting technique. However, Lai et al. (166) encountered a higher rate for perforation of the membrane in patients who received TSFE with bone graft rather than the graftless group, probably because of the additional pressure that the graft material exerted on the membrane. A similar systematic review to this one was conducted by Silva et al. (167), a meta-analysis was also performed, 667 implants installed in the maxillary sinuses with biomaterial and 201 with only the clot were analyzed. The authors only studied the survival rate and complications but did not encounter statistically significant

difference for these variables between the two groups, reinforcing the validity of the findings of this review about the lack of connection between complications and lower survival rates associated with the interposition or not of bone graft in TSFE.

The strengths of this review can be found importantly in the materials and methods used, since three reviewers independently and blindly selected the articles from an initial pool of 1184 records and solved any disagreement through discussion, the inter examiner agreement using the kappa coefficient resulted in an almost perfect agreement. To complete the research a cross-searching of cited references in the studies that were eligible after the full-text screening was carried out. Also, a manual search was done in seven international journals. Another strength of this review is that any of the methodologies adopted had the goal of rendering this review transparent, in the sense that the study can be reproduced by following the same steps mentioned in the materials and methods. In fact, every step of the screening process can be demonstrated, for practical reasons the screening by title and abstract can not be included in the appendix, however it can be exhibited by the author if requested. No filter except the time range was applied in the databases when searching for records, in this way a greater pool of articles was obtained. The data extracted is reported accurately in the results by tables and adequate summaries of the studies. Validated quality assessments for risk of bias were used to determine the quality of each of the studies.

This review had several limitations, to begin with, three databases were used for the electronic research, and only articles written in english, italian and spanish language were considered reducing the number of potential records found in the search. Also, a smaller number of implants than expected was analyzed, the graftless sample had less implants than the grafted sample. More limitations raised because articles such as the ones published by Nedir et al. (2013) (154) and Nedir et al. (2017) (152) were analyzing the same sample of patients which received TSFE with or without bone graft. However, they both had to be included in this review as they complemented each other with information, the same was found for the articles of the authors Si et al. (151) and Quian et al. (153), again, both articles were included as they reported data on the same sample of patients but at different follow up times, and the information of one article

complemented the other. This led to a situation where a smaller sample than expected was found in relation to the overall number of articles. When analyzing the results, the two studies of Nedir et al. (2013) (154) and Nedir et al. (2017) (152) and the two studies of Si et al. (151) and Quian et al. (153) were considered as one complete study without counting the double amount of data. Another limitation was that not all the studies included used the same unit of measure to record their data, one study (156) measured EBG in cubic centimeters instead of millimeters, therefore it could not be compared directly with the rest of the studies. There were also differences between the materials used in the studies, thus only the articles which operated under the same conditions could be compared at same follow up times. This led to more small samples to analyze which sometimes could cause numerical deviations, like it was noted when measuring the weighted average of EBG and MBL at 60 months, in this case a raise in values can be noted since one study (157) used longer implants and generated more intrasinus implant protrusion which resulted in higher values in terms of EBG and MBL. Some studies (151–154,157) had a major limitation, which was the use of 2-dimensional radiographs to assess the EBG, however the rest of the studies (155,156,158) used 3-dimensional imaging CBCT to evaluate the outcomes and had similar results. Verdugo et al. (157) provided their data outcome at only one follow up of 64.6 months, which was a mean of all the follow ups, this was not in line with all the other articles which instead reported data at different follow ups.

Nevertheless, this review had interesting outcomes that should be considered when operating clinically, oral and maxillofacial surgeons should be aware that graft material is not needed to increase the clinical success of implants placed using TSFE technique, if an adequate primary stability is achieved. The real need of the insertion of graft material along with TSFE should be questioned since avoiding it could be indifferent, if not beneficial for the surgeon and the patient, in terms of economic cost of graft material and healing time, since autogenous grafts are obtained from another part of the patient's body and therefore it could cause harm to the donor site. The findings reported in this review underline the importance of future investigation on this topic, since it can result in benefits for oral surgeons and patients receiving the treatment. Conducting a meta-analysis of this review can be an interesting example of future investigation, since

much data of the studies is already reported in the results in the schematic form of spreadsheets. A meta-analysis will give a more precise understanding on the degree of statistical significance of the results, also more findings related to the influence of different factors like smoking, gender, biomaterial, length and diameter of the implants used and make of implants can be analyzed statistically. It would be important for future investigators to be able to study a larger sample of implants placed with TSFE with or without bone graft since this study had the limitation of a relatively small sample. Also, future investigators should consider if the degree of patient satisfaction changes or not when the bone graft is avoided, since not enough evidence was found in order to determine this outcome.

6. CONCLUSIONS

It can be concluded that in the first year after placement, the grafted implants reported moderately higher values of endosinus bone gain compared to the non-grafted implants. In the first year after location of the implants the marginal bone loss was found to be slightly higher in non-grafted implants. After a period of three years, both values of endosinus bone gain and marginal bone loss resulted similar, regardless of the grafting technique. No complications were associated to the grafting technique and no significant differences in terms of implant survival rate were found between the implants placed with or without bone graft. The degree of patient satisfaction after a transcrestal sinus elevation with or without bone graft could not be evaluated because no sufficient data was found.

Aknowledgements

This review did not receive any financial or non-financial support.

Conflicts of interest

The authors have no conflict of interest to declare.

7. REFERENCES

1. Pjetursson BE, Lang NP. Sinus floor elevation utilizing the transalveolar approach. *Periodontol 2000*. 2014 Oct;66(1):59–71.
2. Lundgren S, Cricchio G, Hallman M, Jungner M, Rasmusson L, Sennerby L. Sinus floor elevation procedures to enable implant placement and integration: techniques, biological aspects and clinical outcomes. *Periodontol 2000*. 2017 Feb 1;73(1):103–20.
3. Stern A, Green J. Sinus Lift Procedures: An Overview of Current Techniques. *Dental Clinics of North America*. 2012;56(1):219–33.
4. Woo I, Le BT. Maxillary sinus floor elevation: Review of anatomy and two techniques. *Implant Dentist*. 2004;13(1):28–32.
5. Boyne PJ, James RA. Grafting of the maxillary sinus floor with autogenous marrow and bone. *J Oral Surg*. 1980 Aug;38(8):613–6.
6. Tatum H. Maxillary and sinus implant reconstructions. *Dent Clin North Am*. 1986;30 2:207–29.
7. Summers RB. A new concept in maxillary implant surgery: the osteotome technique. *Compendium*. 1994 Feb;15(2):152, 154–6, 158 passim; quiz 162.
8. Whyte A, Boeddinghaus R. The maxillary sinus: Physiology, development and imaging anatomy. *Dentomaxillofac Radiol*. 2019;48(8).
9. Lee DH, Jun BC, Kim DG, Jung MK, Yeo SW. Volume variation of mastoid pneumatization in different age groups: A study by three-dimensional reconstruction based on computed tomography images. *Surg Radiol Anat*. 2005;27(1):37–42.
10. Molvær OI, Vallersnes FM, Kringlebotn M. The size of the middle ear and the mastoid air cell: System measured by an acoustic method. *Acta Oto-Laryngol*. 1978;85(1–6):24–32.
11. Gosau M, Rink D, Driemel O, Draenert FG. Maxillary sinus anatomy: A cadaveric study with clinical implications. *Anat Rec (Hoboken)*. 2009;292(3):352–4.
12. Kim SH, Kim KH, Seo BM, Koo KT, Kim TI, Seol YJ, et al. Alveolar Bone Regeneration by Transplantation of Periodontal Ligament Stem Cells and Bone Marrow Stem Cells in a Canine Peri-Implant Defect Model: A Pilot Study. *J. Periodontol*. 2009;80(11):1815–23.
13. Stern A, Green J. Sinus Lift Procedures: An Overview of Current Techniques. *Dent Clin North Am*. 2012;56(1):219–33.

14. Gudis DA, Cohen NA. Cilia Dysfunction. *Otolaryngol Clin North Am.* 43(3):461–72.
15. Whyte A, Boeddinghaus R. Imaging of odontogenic sinusitis. *Clin Radiol.* 2019;74(7):503–16.
16. Kalyvas D, Kapsalas A, Paikou S, Tsiklakis K. Thickness of the Schneiderian membrane and its correlation with anatomical structures and demographic parameters using CBCT tomography: a retrospective study. *Int J. Implant Dent.* 2018;4(1):2–9.
17. Al-Bar MH, Lieberman SM, Casiano RR. Surgical anatomy and embryology of the frontal sinus. *The Frontal Sinus, Second Edition.* 2016;15–33.
18. Iwanaga J, Wilson C, Lachkar S, Tomaszewski KA, Walocha JA, Tubbs RS. Clinical anatomy of the maxillary sinus: Application to sinus floor augmentation. *Anat Cell Biol.* 2019;52(1):17–24.
19. Kqiku L, Biblekaj R, Weiglein AH, Kqiku X, Städtler P. Arterial blood architecture of the maxillary sinus in dentate specimens. *Croat Med J.* 2013;54(2):180–4.
20. Flanagan D. Arterial supply of maxillary sinus and potential for bleeding complication during lateral approach sinus elevation. *Implant Dent.* 2005;14(4):336–9.
21. Lim HC, Kim S, Kim DH, Herr Y, Chung JH, Shin S il. Factors Affecting Maxillary Sinus Pneumatization Following Posterior Maxillary Tooth Extraction. Vol. 51, *J. Periodontal Implant Sci.* 2021. 51(4):285-295.
22. Jun BC, Song SW, Park CS, Lee DH, Cho KJ, Cho JH. The analysis of maxillary sinus aeration according to aging process; volume assessment by 3-dimensional reconstruction by high-resolucional CT scanning. *Otolaryngol Head Neck Surg.* 2005;132(3):429–34.
23. Hill CA, Richtsmeier JT. A quantitative method for the evaluation of three-dimensional structure of temporal bone pneumatization. *J. Hum Evol.* 2008;55(4):682–90.
24. Kim J, Song SW, Cho JH, Chang KH, Jun BC. Comparative study of the pneumatization of the mastoid air cells and paranasal sinuses using three-dimensional reconstruction of computed tomography scans. *Surg Radiol Anat.* 2010;32(6):593–9.
25. Farina R, Pramstraller M, Franceschetti G, Pramstraller C, Trombelli L. Alveolar ridge dimensions in maxillary posterior sextants: A retrospective comparative study of dentate and edentulous sites using computerized tomography data. *Clin Oral Implant Res.* 2011;22(10):1138–44.
26. Levi I, Halperin-Sternfeld M, Horwitz J, Zigdon-Giladi H, Machtei EE. Dimensional changes of the maxillary sinus following tooth extraction in the posterior maxilla

- with and without socket preservation. *Clinical Implant Dent Relat Res*. 2017;19(5):952–8.
27. Gu Y, Sun C, Wu D, Zhu Q, Leng D, Zhou Y. Evaluation of the relationship between maxillary posterior teeth and the maxillary sinus floor using cone-beam computed tomography. *BMC Oral Health*. 2018;18(1):164.
 28. Tian XM, Qian L, Xin XZ, Wei B, Gong Y. An analysis of the proximity of maxillary posterior teeth to the maxillary sinus using cone-beam computed tomography. *J Endod*. 2016;42(3):371–7.
 29. Jensen OT, Shulman LB, Block MS, Iacono VJ. Report of the Sinus Consensus Conference of 1996. *Int J Oral Maxillofac Implants*. 1998;13 Suppl:11–45.
 30. Kaufman E. Maxillary sinus elevation surgery. *Dent Today*. 2002;21(9):96–101.
 31. Chiapasco M, Zaniboni M, Rimondini L. Dental implants placed in grafted maxillary sinuses: A retrospective analysis of clinical outcome according to the initial clinical situation and a proposal of defect classification. *Clin Oral Implants Res*. 2008;19(4):416–28.
 32. Cawood JI, Howell RA. A classification of edentulous jaws. *Int J Oral Maxillofac Surg*. 1988;17(13):232–6.
 33. Chiapasco M, Zaniboni M. Methods to Treat the Edentulous Posterior Maxilla: Implants With Sinus Grafting. *J Oral Maxillofac Surg*. 2009;67(4):867–71.
 34. Ta Velli L, Borgonovo AE, Re D, Maiorana C. Sinus presurgical evaluation: A literature review and a new classification proposal. *Minerva Stomatol*. 2017;66(3):115–31.
 35. Pal U, Sharma N, Singh R, Singh N, Mahammad S, Mandhyan D, et al. Direct vs. indirect sinus lift procedure: A comparison. *Natl J of Maxillofac Surg*. 2012;3(1):31.
 36. Stacchi C, Andolsek F, Berton F, Perinetti G, Navarra C, di Lenarda R. Intraoperative Complications During Sinus Floor Elevation with Lateral Approach: A Systematic Review. *Int J Oral Maxillofac Implants*. 2017;32(3):e107–18.
 37. Zitzmann NU, Schärer P. Sinus elevation procedures in the resorbed posterior maxilla: Comparison of the crestal and lateral approaches. *Oral Surg Oral Med Oral Pathol Oral Radiol Endod*. 1998;85(1):8–17.
 38. Pizzini A, Basma HS, Li P, Geurs NC, Abou-Arraj R v. The impact of anatomic, patient and surgical factors on membrane perforation during lateral wall sinus floor elevation. *Clin Oral Implants Res*. 2021;32(3):274–84.
 39. Danesh-Sani SA, Loomer PM, Wallace SS. A comprehensive clinical review of maxillary sinus floor elevation: anatomy, techniques, biomaterials and

- complications Seyed Amir Danesh-Sani. *Br J Oral Maxillofac Surg*. 2016;54(7):724–30.
40. Marx RE, Garg AK. A novel aid to elevation of the sinus membrane for the sinus lift procedure. *Implant Dent*. 2002;11(3):268–71.
 41. Romero-Millán J, Martorell-Calatayud L, Peñarrocha M, García-Mira B. Indirect osteotome maxillary sinus floor elevation: An update. *J Oral Implantol*. 2012;38(6):799–804.
 42. Zhou Y, Shi Y, Si M, Wu M, Xie Z. The comparative evaluation of transcrestal and lateral sinus floor elevation in sites with residual bone height ≤ 6 mm: A two-year prospective randomized study. *Clin Oral Implants Res*. 2021 Feb;32(2):180-191.
 43. Gonzalez S, Tuan MC, Ahn KM, Nowzari H. Crestal approach for maxillary sinus augmentation in patients with ≤ 4 mm of residual alveolar bone. *Clin Implant Dent Relat Res*. 2014 Dec;16(6):827–35.
 44. Thomas TJ, Bidra AS. Internal Sinus Membrane Elevation in Patients With Less Than 5 mm Residual Bone Height. *Compend Contin Educ Dent*. 2018 May;39(5):e13–6.
 45. Rammelsberg P, Pahle J, Büsch C, Zenthöfer A. Long-term apical bone gain after implant placement combined with internal sinus-floor elevation without graft. *BMC Oral Health*. 2020 Jul;20(1):197.
 46. Nedir R, Nurdin N, Huynh-Ba G, Bischof M. Change in Crown-to-Implant Ratio of Implants Placed in Grafted and Nongrafted Posterior Maxillary Sites: A 5-year Prospective Randomized Study. *Int J Oral Maxillofac Implants*. 2019;34(5):1231–6.
 47. Andrés-García R, Ríos-Santos JV, Herrero-Climent M, Bullón P, Fernández-Farhall J, Gómez-Menchero A, et al. Sinus floor elevation via an osteotome technique without biomaterials. *International Int J Environ Res Public Health*. 2021;18(3):1–13.
 48. Bruschi GB, Crespi R, Capparè P, Gherlone E. Transcrestal sinus floor elevation: a retrospective study of 46 patients up to 16 years. *Clin Implant Dent Relat Res*. 2012 Oct;14(5):759–67.
 49. Gu YX, Shi JY, Zhuang LF, Qian SJ, Mo JJ, Lai HC. Transalveolar sinus floor elevation using osteotomes without grafting in severely atrophic maxilla: a 5-year prospective study. *Clin Oral Implants Res*. 2016 Jan;27(1):120–5.
 50. Qabbani A, al Bayatti SW, Hasan H, Samsudin AB, al Kawas S. Clinical and radiological evaluation of sinus membrane osteogenicity subsequent to internal sinus lifting and implant placement *J Craniofac Surg*. 2020;31(3):E233–6.

51. Volpe S, Colasanti U, Pagliani L. Coagulo e membrana sinusale: connubio ideale per la rigenerazione ossea all'interno dei seni mascellari. *Dent Cadmos*. 2016;84(5):282–90.
52. Qabbani A, al Bayatti SW, Hasan H, Samsudin AB, al Kawas S. Clinical and radiological evaluation of sinus membrane osteogenicity subsequent to internal sinus lifting and implant placement. *Journal of Craniofacial Surgery*. 2020;31(3):E233–6.
53. Santoro M, Pippi R. Intrasinus Bone Gain with the Osteotome Sinus Floor Elevation Technique: A Review of the Literature. *Int J Oral Maxillofac Implants*. 2018;33(5):995–1002.
54. Duan DH, Fu JH, Qi W, Du Y, Pan J, Wang HL. Graft-Free Maxillary Sinus Floor Elevation: A Systematic Review and Meta-Analysis. *J Periodontol*. 2017;88(6):550–64.
55. Toffler M. Osteotome-mediated sinus floor elevation: a clinical report. *Int J Oral Maxillofac Implants*. 2014;19(2):266–73.
56. Rammelsberg P, Kilian S, Büsch C, Kappel S. The effect of transcrestal sinus-floor elevation without graft on the long-term prognosis of maxillary implants. *J Clin Periodontol*. 2020;47(5):640–8.
57. Gu YX, Shi JY, Zhuang LF, Qian SJ, Mo JJ, Lai HC. Transalveolar sinus floor elevation using osteotomes without grafting in severely atrophic maxilla: A 5-year prospective study. *Clin Oral Implants Res*. 2016;27(1):120–5.
58. Nedir R, Nurdin N, Vazquez L, Abi Najm S, Bischof M. Osteotome Sinus Floor Elevation without Grafting: A 10-Year Prospective Study. *Clin Implant Dent Relat Res*. 2016 Jun;18(3):609–17.
59. Volpe S, Lanza M, Verrocchi D, Sennerby L. Clinical outcomes of an osteotome technique and simultaneous placement of Neoss implants in the posterior maxilla. *Clin Implant Dent Relat Res*. 2013 Feb;15(1):22–8.
60. Brizuela A, Martín N, Fernández-Gonzalez FJ, Larrazábal C, Anta A. Osteotome sinus floor elevation without grafting material: Results of a 2-year prospective study. *J Clin Exp Dent*. 2014 Dec;6(5):e479-84.
61. He L, Chang X, Liu Y. Sinus floor elevation using osteotome technique without grafting materials: A 2-year retrospective study. *Clin Oral Implants Res*. 2013;24(A100):63–7.
62. El Hage M, Nurdin N, Najm S, Bischof M, Nedir R. Osteotome Sinus Floor Elevation Without Grafting: A 10-Year Study of Cone Beam Computerized Tomography vs Periapical Radiography. *Int J Periodontics Restorative Dent*. 2019;39(3):e89–97.

63. Caban J, Fermergård R, Abtahi J. Long-term evaluation of osteotome sinus floor elevation and simultaneous placement of implants without bone grafts: 10-Year radiographic and clinical follow-up. *Clin Implant Dent Relat Res.* 2017 Dec;19(6):1023–33.
64. French D, Nadji N, Shariati B, Hatzimanolakis P, Larjava H. Survival and Success Rates of Dental Implants Placed Using Osteotome Sinus Floor Elevation Without Added Bone Grafting: A Retrospective Study with a Follow-up of up to 10 Years. *Int J Periodontics Restorative Dent.* 2016;36 Suppl:s89-97.
65. Rammelsberg P, Mahabadi J, Eiffler C, Koob A, Kappel S, Gabbert O. Radiographic monitoring of changes in bone height after implant placement in combination with an internal sinus lift without graft material. *Clin Implant Dent Relat Res.* 2015 Jan;17 Suppl 1:e267-74.
66. Cricchio G, Imburgia M, Sennerby L, Lundgren S. Immediate loading of implants placed simultaneously with sinus membrane elevation in the posterior atrophic maxilla: A two-year follow-up study on 10 patients. *Clin Implant Dent Relat Res.* 2014;16(4):609–17.
67. Nedir R, Nurdin N, Khoury P, Bischof M. Short Implants Placed with or without Grafting in Atrophic Sinuses: The 3-Year Results of a Prospective Randomized Controlled Study. *Clin Implant Dent Relat Res.* 2016 Feb;18(1):10–8.
68. Si M si, Shou Y wen, Shi Y tian, Yang G li, Wang H ming, He F ming. Long-term outcomes of osteotome sinus floor elevation without bone grafts: a clinical retrospective study of 4-9 years. *Clin Oral Implants Res.* 2016;27(11):1392–400.
69. Najm SA, Nurdin N, el Hage M, Bischof M, Nedir R. Osteotome Sinus Floor Elevation Without Grafting: A 10-Year Clinical and Cone-Beam Sinus Assessment. *Implant Dent.* 2018;27(4):439–44.
70. Fermergård R, Åstrand P. Osteotome Sinus Floor Elevation without Bone Grafts - A 3-Year Retrospective Study with Astra Tech Implants. *Clin Implant Dent Relat Res.* 2012;14(2):198–205.
71. Rammelsberg P, Kilian S, Büsch C, Kappel S. The effect of transcrestal sinus-floor elevation without graft on the long-term prognosis of maxillary implants. *J Clin Periodontol.* 2020 May 1;47(5):640–8.
72. Cho YS, Chong D, Yang SM, Kang B. Hydraulic transcrestal sinus lift: Different patterns of elevation in pig sinuses. *Implant Dent.* 2017;26(5):706–10.
73. Rao GS, Reddy SK. Antral balloon sinus elevation and grafting prior to dental implant placement: Review of 34 cases. *Int J Oral Maxillofac Implants.* 2014;29(2):414–8.
74. López-Quiles J, Melero-Alarcón C, Cano-Duran JA, Sánchez-Martínez-Sauceda EI, Ortega R. Maxillary sinus balloon lifting and deferred implantation of 50

- osseointegrated implants: a prospective, observational, non-controlled study. *Int J Oral Maxillofac Surg*. 2018;47(10):1343–9.
75. Draenert GF, Eisenmenger W. A new technique for the transcrestal sinus floor elevation and alveolar ridge augmentation with press-fit bone cylinders: a technical note. *J craniomaxillofac surg* . 2007;35(4–5):201–6.
 76. Isidori M, Genty C, David-Tchouda S, Fortin T. Sinus floor elevation with a crestal approach using a press-fit bone block: a case series. *Int J Oral Maxillofac Surg*. 2015 Sep;44(9):1152–9.
 77. Kim JM, Sohn DS, Bae MS, Moon JW, Lee JH, Park IS. Flapless transcrestal sinus augmentation using hydrodynamic piezoelectric internal sinus elevation with autologous concentrated growth factors alone. *Implant Dentist*. 2014;23(2):168–74.
 78. Rodda A, Koduganti RR, Manne HK, Gullapelli P, Jaahnavi Devarampati L. Implant Placement Post Maxillary Sinus Lift Using Osseodensification Concept: A Case Report. *Cureus*. 2022 Jan 31;14(1):e21756.
 79. Trisi P, Berardini M, Falco A, Podaliri Vulpiani M. New osseodensification implant site preparation method to increase bone density in low-density bone: In vivo evaluation in sheep. *Implant Dent*. 2016;25(1):24–31.
 80. Page MJ, McKenzie JE, Bossuyt PM, Boutron I, Hoffmann TC, Mulrow CD, et al. The PRISMA 2020 statement: an updated guideline for reporting systematic reviews. *BMJ*. 2021 Mar;372:n71.
 81. Sterne JAC, Savović J, Page MJ, Elbers RG, Blencowe NS, Boutron I, et al. RoB 2: a revised tool for assessing risk of bias in randomised trials. *BMJ*. 2019 Aug;366:l4898.
 82. Sterne JA, Hernán MA, Reeves BC, Savović J, Berkman ND, Viswanathan M, et al. ROBINS-I: a tool for assessing risk of bias in non-randomised studies of interventions. *BMJ*. 2016 Oct;355:i4919.
 83. Zahedpasha A, Ghassemi A, Bijani A, Haghanifar S, Majidi MS, Ghorbani ZM. Comparison of Bone Formation After Sinus Membrane Lifting Without Graft or Using Bone Substitute “Histologic and Radiographic Evaluation.” *J Oral Maxillofac Surg*. 2021;79(6):1246–54.
 84. Borges FL, Dias RO, Piattelli A, Onuma T, Gouveia Cardoso LAP, Salomão M, et al. Simultaneous Sinus Membrane Elevation and Dental Implant Placement Without Bone Graft: A 6-Month Follow-Up Study. *J Periodontol*. 2011;82(3):403–12.
 85. Cricchio G, Sennerby L, Lundgren S. Sinus bone formation and implant survival after sinus membrane elevation and implant placement: a 1-to 6-year follow-up study. *Clin Oral Implants Res*. 2011;22(10):1200–12.

86. Riben C, Thor A. Follow-Up of the Sinus Membrane Elevation Technique for Maxillary Sinus Implants without the Use of Graft Material. *Clin Implant Dent Relat Res.* 2016;18(5):895–905.
87. Tomruk CO, Sencift MK, Capar GD. Prevalence of sinus floor elevation procedures and survival rates of implants placed in the posterior maxilla. *Biotechnol Biotechnolog Equipment.* 2016;30(1):134–9.
88. Malchiodi L, Cucchi A, Ghensi P, Caricasulo R, Nocini PF. The “Alternating Osteotome Technique”: a surgical approach for combined ridge expansion and sinus floor elevation. A multicentre prospective study with a three-year follow-up.” *Biotechnol Biotechnolog Equipment.* 2016;30(4):762–9.
89. Lombardo G, Marincola M, Signoriello A, Corrocher G, Nocini PF. Single-Crown, Short and Ultra-Short Implants, in Association with Simultaneous Internal Sinus Lift in the Atrophic Posterior Maxilla: A Three-Year Retrospective Study. *Materials (Basel).* 2020 May 11;13(9):2208.
90. Soydan SS, Cubuk S, Bayrak B, Uckan S. Comparative Evaluation of Simultaneous Maxillary Sinus Floor Elevation and Implant Placement with Residual Bone Heights Greater or Less than 5 mm. *Int J Oral Maxillofac Implants.* 2015;30(1):179–83.
91. Lumbau AI, Meloni SM, Tallarico M, Melis L, Spano G, Baldoni E, et al. Implant Placement Following Crestal Sinus Lift with Sequential Drills and Osteotomes: Five Years after Final Loading Results from a Retrospective Study. *J Funct Biomater.* 2021 Feb 4;12(1):10.
92. Freiha C, Kassir AR, Ghosn N, Mokbel N, Naaman N, Dagher M. Sub-antral volumetric variation after a modified trephine sinus elevation approach: An 8-month prospective study. *J Osseointeg.* 2021;13(4):227–33.
93. Max A, Walter C, Ehbauer S, Zwiener I, Ziebart T, Al-nawas B, et al. Analysis of implant-failure predictors in the posterior maxilla : A retrospective study of 1395 implants. *Journal of Cranio-Maxillofacial Surgery.* 2015;1–7.
94. Mandelli F, Ghensi P, Vinci R, Mandelli G. Sinus floor elevation with crestal approach and immediately loaded post-extraction implants. *J Indiana Dent Assoc.* 2013;92(1):22–4; quiz 25.
95. Zhen F, Fang W, Jing S, Zuolin W. The use of a piezoelectric ultrasonic osteotome for internal sinus elevation: A retrospective analysis of clinical results. *Int J Oral Maxillofac Implants.* 2012;27(4):920–6.
96. Bensaha T. Outcomes of flapless crestal maxillary sinus elevation under hydraulic pressure. *International Int J Oral Maxillofac Implants.* 2012;27(5):1223–9.

97. Bernardello F, Righi D, Cosci F, Bozzoli P, Soardi Carlo M, Spinato S. Crestal sinus lift with sequential drills and simultaneous implant placement in sites with <5 mm of native bone: A multicenter retrospective study. *Implant Dent.* 2011;20(6):439–44.
98. Baldi D, Menini M, Pera F, Ravera G, Pera P. Sinus floor elevation using osteotomes or piezoelectric surgery. *Int J Oral Maxillofac Surg.* 2011;40(5):497–503.
99. Mazor Z, Kfir E, Lorean A, Mijiritsky E, Horowitz RA. Flapless approach to maxillary sinus augmentation using minimally invasive antral membrane balloon elevation. *Implant Dent.* 2011;20(6):434–8.
100. Nizam N, Gürlek Ö, Kaval ME. Extra-Short Implants with Osteotome Sinus Floor Elevation: A Prospective Clinical Study. *Int J Oral Maxillofac Implants.* 2020 Mar/Apr;35(2):415-422.
101. Shi JY, Qian SJ, Gu YX, Qiao SC, Tonetti MS, Lai HC. Long-term outcomes of osteotome sinus floor elevation without grafting in severely atrophic maxilla: A 10-year prospective study. *J Clin Periodontol.* 2020 Dec;47(12):1528–35.
102. Shi JY, Li Y, Qiao SC, Gu YX, Xiong YY, Lai HC. Short versus longer implants with osteotome sinus floor elevation for moderately atrophic posterior maxillae: A 1-year randomized clinical trial. *J Clin Periodontol.* 2019 Aug;46(8):855–62.
103. Nahlieli O, Boiangiu A, Abramson A, Aba M, Nahlieli D, Srouji S. Graftless sinus floor augmentation with an internal-port implant: long-term experience. *Quintessence Int.* 2019;50(7):560–7.
104. Wang Q, Li D, Tang ZH. [Sinus floor elevation and simultaneous dental implantation: A long term retrospective study of sinus bone gain]. *Beijing Da Xue Xue Bao Yi Xue Ban.* 2019 Oct 18;51(5):925-930.
105. Zill A, Precht C, Beck-Broichsitter B, Sehner S, Smeets R, Heiland M, et al. Implants inserted with graftless osteotome sinus floor elevation - A 5-year post-loading retrospective study. *Eur J Oral Implantol.* 2016;9(3):277–89.
106. Magdy M, Abdelkader MA, Alloush S, Fawzy El-Sayed KM, Nawwar AA, Shoeib M, et al. Ultra-short versus standard-length dental implants in conjunction with osteotome-mediated sinus floor elevation: A randomized controlled clinical trial. *Clin Implant Dent Relat Res.* 2021 Aug;23(4):520–9.
107. Shi JY, Lai YR, Qian SJ, Qiao SC, Tonetti MS, Lai HC. Clinical, radiographic and economic evaluation of short-6-mm implants and longer implants combined with osteotome sinus floor elevation in moderately atrophic maxillae: A 3-year randomized clinical trial. *J Clin Periodontol.* 2021 May;48(5):695–704.
108. Kakar A, Sripathi Rao BH, Deshpande N, Hegde S, Kohli A, Patney A, et al. Osteotome-mediated sinus floor elevation using an in situ hardening biphasic

- calcium phosphate bone graft substitute compared to xenograft: A randomized controlled clinical trial *Indian J Dent Res.* 2021 Jan-Feb;32(1):61-68.
109. Gai L, Luo X, Guan Y, He F. Comparative Evaluation of Endo-sinus Bone Augmentation After Osteotome Sinus Floor Elevation Without Grafting Using Two Radiographic Methods. *Int J Oral Maxillofac Implants.* 2021;36(1):154–64.
 110. Li P, Piao MZ, Hu HC, Wang Y, Zhao YJ, Shen XJ. [Radiography study on osteotome sinus floor elevation with placed implant simultaneously with no graft augmentation]. *Beijing Da Xue Xue Bao Yi Xue Ban.* 2020 Dec 24;53(1):95-101.
 111. Shi JY, Gu YX, Qiao SC, Zhuang LF, Zhang XM, Lai HC. Clinical evaluation of short 6-mm implants alone, short 8-mm implants combined with osteotome sinus floor elevation and standard 10-mm implants combined with osteotome sinus floor elevation in posterior maxillae: study protocol for a randomized controlled trial. *Trials.* 2015 Jul;16:324.
 112. Bae OY, Kim YS, Shin SY, Kim WK, Lee YK, Kim SH. Clinical Outcomes of Reamer- vs Osteotome-Mediated Sinus Floor Elevation with Simultaneous Implant Placement: A 2-Year Retrospective Study. *Int J Oral Maxillofac Implants.* 2015 Jul-Aug;30(4):925-30.
 113. He L, Chang X, Liu Y. Sinus floor elevation using osteotome technique without grafting materials: a 2-year retrospective study. *Clin Oral Implants Res.* 2013 Aug;24 Suppl A:63–7.
 114. Crespi R, Capparè P, Gherlone E. Sinus floor elevation by osteotome: hand mallet versus electric mallet. A prospective clinical study. *Int J Oral Maxillofac Implants.* 2012;27(5):1144–50.
 115. Santagata M, Guariniello L, D’amato S, Tozzi U, Rauso R, Tartaro G. Augmentation of atrophic posterior maxilla by short implants and osteotome technique. *Stomatologija.* 2012;14(3):85–8.
 116. Xiao HJ, Yang YD, Xu S, Sun AJ, Liu ZH. [Clinical study of osteotome sinus floor elevation without grafting and with simultaneous implants placement]. *Zhonghua Kou Qiang Yi Xue Za Zhi.* 2011 May;46(5):272-5.
 117. Galindo-Moreno P, Fernández-Jiménez A, Avila-Ortiz G, Silvestre FJ, Hernández-Cortés P, Wang HL. Marginal bone loss around implants placed in maxillary native bone or grafted sinuses: a retrospective cohort study. *Clin Oral Implants Res.* 2014 Mar;25(3):378–84.
 118. Chandra RV, Suvvari N, Reddy AA. Trephine Core Procedure Versus Bone-Added Osteotome Sinus Floor Elevation in the Augmentation of the Sinus Floor: A Comparative Clinical and Radiographic Study. *Int J Oral Maxillofac Implants.* 2018;33(2):425–32.

119. Stefanski S, Svensson B, Thor A. Implant survival following sinus membrane elevation without grafting and immediate implant installation with a one-stage technique: an up-to-40-month evaluation. *Clin Oral Implants Res.* 2017 Nov;28(11):1354-1359.
120. Bruschi GB, Crespi R, Capparè P, Bravi F, Bruschi E, Gherlone E. Localized management of sinus floor technique for implant placement in fresh molar sockets. *Clin Implant Dent Relat Res.* 2013 Apr;15(2):243–50.
121. Senyilmaz DP, Kasaboglu O. Osteotome sinus floor elevation without bone grafting and simultaneous implant placement in the atrophic maxilla: a pilot study. *Indian J Dent Res.* 2011 Nov-Dec;22(6):786-9.
122. Kim JM, Sohn DS, Heo JU, Park JS, Jung HS, Moon JW, et al. Minimally invasive sinus augmentation using ultrasonic piezoelectric vibration and hydraulic pressure: a multicenter retrospective study. *Implant Dent.* 2012 Dec;21(6):536–42.
123. Yang DW, Xiao JY, Zhang P, Lu BY, Liang X. Retrospective study on the merits of bone grafts and the influence of implant protrusion length after osteotome sinus elevation surgery. *Hua Xi Kou Qiang Yi Xue Za Zhi.* 2021 Oct 1;39(5):570-575.
124. Altintas NY, Senel FC, Kayipmaz S, Taskesen F, Pampu AA. Comparative radiologic analyses of newly formed bone after maxillary sinus augmentation with and without bone grafting. *J Oral Maxillofac Surg.* 2013 Sep;71(9):1520-30.
125. Thoma DS, Haas R, Tutak M, Garcia A, Schincaglia G, Hämmeler CHF. Randomized controlled multicentre study comparing short dental implants (6 mm) versus longer dental implants (11-15 mm) in combination with sinus floor elevation procedures. Part 1: demographics and patient-reported outcomes at 1 year of loading. *J Clin Periodontol.* 2015 Jan;42(1):72–80.
126. Zhang Y xin, Li C lun, Shu R, Xie Y feng, Liu X feng, Liu D li. [A clinical study of osteotome sinus floor elevation and simultaneous implant placement in the periodontally compromised patients]. *Shanghai Kou Qiang Yi Xue.* 2013 Aug;22(4):423–7.
127. Jiang YH, Tao HB, Jin XM, Li XK. [Clinical evaluation of simple maxillary sinus elevation with simultaneous implant in patients with serious posterior maxillary deficiency]. *Shanghai Kou Qiang Yi Xue.* 2017 Dec;26(6):633–6.
128. Shayesteh YS, Khojasteh A, Siadat H, Monzavi A, Bassir SH, Hossaini M, Alikhasi M. A comparative study of crestal bone loss and implant stability between osteotome and conventional implant insertion techniques: a randomized controlled clinical trial study. *Clin Implant Dent Relat Res.* 2013 Jun;15(3):350-7.
129. Zhang XM, Shi JY, Gu YX, Qiao SC, Mo JJ, Lai HC. Clinical Investigation and Patient Satisfaction of Short Implants Versus Longer Implants with Osteotome Sinus

- Floor Elevation in Atrophic Posterior Maxillae: A Pilot Randomized Trial. *Clin Implant Dent Relat Res.* 2017 Feb;19(1):161–6.
130. Rammelsberg P, Schmitter M, Gabbert O, Lorenzo Bermejo J, Eiffler C, Schwarz S. Influence of bone augmentation procedures on the short-term prognosis of simultaneously placed implants. *Clin Oral Implants Res.* 2012 Oct;23(10):1232-7.
 131. Sahrman P, Naenni N, Jung RE, Held U, Truninger T, Hämmerle CHF, et al. Success of 6-mm Implants with Single-Tooth Restorations: A 3-year Randomized Controlled Clinical Trial. *J Dent Res.* 2016 Jun;95(6):623–8.
 132. Bruckmoser E, Gruber R, Steinmassl O, Eder K, Watzinger F, Bayerle-Eder M, Jesch P. Crestal Sinus Floor Augmentation Using Hydraulic Pressure and Vibrations: A Retrospective Single Cohort Study. *Int J Oral Maxillofac Implants.* 2018 Sep/Oct;33(5):1149-1154.
 133. Xiao F, Zhao BD, Wang WY, Feng AJ, Guo SW, Zhang XJ. [Clinical study of transcresal maxillary sinus floor elevation with the disk-up sinus reamer]. *Zhonghua Kou Qiang Yi Xue Za Zhi.* 2011 Jun;46(6):321-5.
 134. Crespi R, Toti P, Covani U, Crespi G, Menchini-Fabris GB. Clinical and Radiographic Evaluation of Modified Transalveolar Two-Step Osteotome-Mediated Localized Maxillary Sinus Elevation: A Retrospective Computed Tomography Study with a 3-Year Follow-up. *Int J Oral Maxillofac Implants.* 2021;36(3):553–60.
 135. Chen Y, Yuan S, Zhou N, Man Y. Transcresal sinus floor augmentation with immediate implant placement applied in three types of fresh extraction sockets: A clinical prospective study with 1-year follow-up. *Clin Implant Dent Relat Res.* 2017 Dec;19(6):1034–43.
 136. Ahn SH, Park EJ, Kim ES. Reamer-mediated transalveolar sinus floor elevation without osteotome and simultaneous implant placement in the maxillary molar area: clinical outcomes of 391 implants in 380 patients. *Clin Oral Implants Res.* 2012 Jul;23(7):866–72.
 137. Wang RF, Zhao D, Lin HY, Liu M, Wang WQ. [Clinical evaluation of two transalveolar methods for sinus augmentation with placing 1 204 implants immediately]. *Zhonghua Kou Qiang Yi Xue Za Zhi.* 2018 Dec 9;53(12):821-825.
 138. Fugazzotto PA. Success and Failure Rates of 1,344 6- to 9-mm-Length Rough-Surface Implants Placed at the Time of Transalveolar Sinus Elevations, Restored with Single Crowns, and Followed for 60 to 229 Months in Function. *Int J Oral Maxillofac Implants.* 2017;32(6):1359–63.
 139. Lin S, Feng Y, Xie J, Song Y, Xie C, Li D. [Maxillary sinus floor augmentation using the transalveolar technique with simultaneous placement of dental implants: a 5-year clinical retrospective study]. *Zhonghua Kou Qiang Yi Xue Za Zhi.* 2014 Mar;49(3):161-5.

140. French D, Nadji N, Liu SX, Larjava H. Trifactorial classification system for osteotome sinus floor elevation based on an observational retrospective analysis of 926 implants followed up to 10 years. *Quintessence Int.* 2015 Jun;46(6):523–30.
141. Pozzi A, Moy PK. Minimally invasive transcresal guided sinus lift (TGSL): A clinical prospective proof-of-concept cohort study up to 52 months. *Clin Implant Dent Relat Res.* 2014;16(4):582–93.
142. Bruschi GB, Bruschi E, Papetti L. Flapless Localised Management of Sinus Floor (LMSF) for trans-cresal sinus floor augmentation and simultaneous implant placement. A retrospective non-randomized study: 5-year of follow-up. *Heliyon.* 2021 Sep;7(9):e07927.
143. Jain S, Solanki A. A dynamic surgical navigational approach for immediate implantation and transcresal sinus augmentation. *J Indian Soc Periodontol.* 2021 Sep-Oct;25(5):451-456.
144. Mahesh L, Agarwal A, Guirado JC, Bali P, Poonia N. Survival of Implants after Indirect Maxillary Sinus Elevation Procedure: A Two Years Longitudinal Study. *J Contemp Dent Pract.* 2019 Apr;20(4):504–7.
145. Carelli S, Passaretti A, Petroni G, Zanza A, Testarelli L, Cicconetti A. Five Years Follow-up of Short Implants Placed in Atrophic Maxilla with Simultaneous Sinus Floor Transcresal Elevation. *Acta Stomatol Croat.* 2021 Jun;55(2):177–85.
146. Gatti F, Gatti C, Tallarico M, Tommasato G, Meloni SM, Chiapasco M. Maxillary Sinus Membrane Elevation Using a Special Drilling System and Hydraulic Pressure: A 2-Year Prospective Cohort Study. *Int J Periodontics Restorative Dent.* 2018;38(4):593–9.
147. Nedir R, Nurdin N, Khoury P, Bischof M. Short Implants Placed with or without Grafting in Atrophic Sinuses: The 3-Year Results of a Prospective Randomized Controlled Study. *Clin Implant Dent Relat Res.* 2016 Feb;18(1):10–8.
148. Nedir R, Nurdin N, Huynh-Ba G, Bischof M. Change in Crown-to-Implant Ratio of Implants Placed in Grafted and Nongrafted Posterior Maxillary Sites: A 5-year Prospective Randomized Study. *Int J Oral Maxillofac Implants.* 2019;34(5):1231–6.
149. Qabbani A al, Bayatti SW al, Hasan H, Samsudin AB, Kawas S al. Clinical and Radiological Evaluation of Sinus Membrane Osteogenicity Subsequent to Internal Sinus Lifting and Implant Placement. *J Craniofac Surg.* 2020;31(3):e233–6.
150. Zhao X, Gao W, Liu F. Clinical evaluation of modified transalveolar sinus floor elevation and osteotome sinus floor elevation in posterior maxillae: study protocol for a randomized controlled trial. *Trials.* 2018 Sep;19(1):489.

151. Si MS, Zhuang LF, Gu YX, Mo JJ, Qiao SC, Lai HC. Osteotome sinus floor elevation with or without grafting: A 3-year randomized controlled clinical trial. *J Clin Periodontol.* 2013;40(4):396–403.
152. Nedir R, Nurdin N, Abi Najm S, el Hage M, Bischof M. Short implants placed with or without grafting into atrophic sinuses: the 5-year results of a prospective randomized controlled study. *Clin Oral Implants Res.* 2017 Jul;28(7):877–86.
153. Qian SJ, Mo JJ, Si MS, Qiao SC, Shi JY, Lai HC. Long-term outcomes of osteotome sinus floor elevation with or without bone grafting: The 10-year results of a randomized controlled trial. *J Clin Periodontol.* 2020 Aug;47(8):1016–25.
154. Nedir R, Nurdin N, Khoury P, Perneger T, Hage M el, Bernard JP, et al. Osteotome sinus floor elevation with and without grafting material in the severely atrophic maxilla. A 1-year prospective randomized controlled study. *Clin Oral Implants Res.* 2013 Nov;24(11):1257–64.
155. Trinh HA, Dam VV, Le B, Pittayapat P, Thunyakitpisal P. Indirect Sinus Augmentation With and Without the Addition of a Biomaterial: A Randomized Controlled Clinical Trial. *Implant Dent.* 2019 Dec;28(6):571–7.
156. Marković A, Mišić T, Calvo-Guirado JL, Delgado-Ruíz RA, Janjić B, Abboud M. Two-Center Prospective, Randomized, Clinical, and Radiographic Study Comparing Osteotome Sinus Floor Elevation with or without Bone Graft and Simultaneous Implant Placement. *Clin Implant Dent Relat Res.* 2016 Oct;18(5):873–82.
157. Verdugo F, Uribarri A, Laksmana T, D'addona A. Long-term stable vertical bone regeneration after sinus floor elevation and simultaneous implant placement with and without grafting. *Clin Implant Dent Relat Res.* 2017 Dec;19(6):1054–60.
158. Yang J, Xia T, Fang J, Shi B. Radiological Changes Associated with New Bone Formation Following Osteotome Sinus Floor Elevation (OSFE): A Retrospective Study of 40 Patients with 18-Month Follow-Up. *Med Sci Monit.* 2018 Jul 5;24:4641-4648.
159. Buser D, Mericske-Stern R, Bernard JP, Behneke A, Behneke N, Hirt HP, et al. Long-term evaluation of non-submerged ITI implants. Part 1: 8-year life table analysis of a prospective multi-center study with 2359 implants. *Clin Oral Implants Res.* 1997 Jun;8(3):161–72.
160. Cochran DL, Buser D, ten Bruggenkate CM, Weingart D, Taylor TM, Bernard JP, et al. The use of reduced healing times on ITI implants with a sandblasted and acid-etched (SLA) surface: early results from clinical trials on ITI SLA implants. *Clin Oral Implants Res.* 2002 Apr;13(2):144–53.
161. Karoussis IK, Brägger U, Salvi GE, Bürgin W, Lang NP. Effect of implant design on survival and success rates of titanium oral implants: a 10-year prospective

- cohort study of the ITI Dental Implant System. Clin Oral Implants Res. 2004 Feb;15(1):8–17.
162. Dragonas P, Katsaros T, Schiavo J, Galindo-Moreno P, Avila-Ortiz G. Osteogenic capacity of the sinus membrane following maxillary sinus augmentation procedures: A systematic review. Int J Oral Implantol (Berl). 2020;13(3):213–32.
 163. Song DS, Kim CH, Kim BJ, Kim JH. Tenting effect of dental implant on maxillary sinus lift without grafting. J Dent Sci. 2020 Sep;15(3):278–85.
 164. Kim YK, Kim SG, Kim BS, Jeong KI. Resorption of bone graft after maxillary sinus grafting and simultaneous implant placement. J Korean Assoc Oral Maxillofac Surg. 2014 Jun;40(3):117–22.
 165. Fermergård R, Åstrand P. Osteotome sinus floor elevation without bone grafts-- a 3-year retrospective study with Astra Tech implants. Clin Implant Dent Relat Res. 2012 Apr;14(2):198–205.
 166. Lai HC, Zhuang LF, Lv XF, Zhang ZY, Zhang YX, Zhang ZY. Osteotome sinus floor elevation with or without grafting: a preliminary clinical trial. Clin Oral Implants Res. 2010 May;21(5):520–6.
 167. Silva L deF, de Lima VN, Faverani LP, de Mendonça MR, Okamoto R, Pellizzer EP. Maxillary sinus lift surgery-with or without graft material? A systematic review. Int J Oral Maxillofac Surg. 2016 Dec;45(12):1570–6.

APPENDIX

Appendix 1

Section and Topic	Item #	Checklist item	Location where item is reported
TITLE			
Title	1	Identify the report as a systematic review.	1
ABSTRACT			
Abstract	2	See the PRISMA 2020 for Abstracts checklist.	1
INTRODUCTION			
Rationale	3	Describe the rationale for the review in the context of existing knowledge.	11
Objectives	4	Provide an explicit statement of the objective(s) or question(s) the review addresses.	13

Section and Topic	Item #	Checklist item	Location where item is reported
METHODS			
Eligibility criteria	5	Specify the inclusion and exclusion criteria for the review and how studies were grouped for the syntheses.	14
Information sources	6	Specify all databases, registers, websites, organisations, reference lists and other sources searched or consulted to identify studies. Specify the date when each source was last searched or consulted.	15
Search strategy	7	Present the full search strategies for all databases, registers and websites, including any filters and limits used.	16
Selection process	8	Specify the methods used to decide whether a study met the inclusion criteria of the review, including how many reviewers screened each record and each report retrieved, whether they worked independently, and if applicable, details of automation tools used in the process.	17
Data collection process	9	Specify the methods used to collect data from reports, including how many reviewers collected data from each report, whether they worked independently, any processes for obtaining or confirming data from study investigators, and if applicable, details of automation tools used in the process.	17
Data items	10a	List and define all outcomes for which data were sought. Specify whether all results that were compatible with each outcome domain in each study were sought (e.g. for all measures, time points, analyses), and if not, the methods used to decide which results to collect.	18
	10b	List and define all other variables for which data were sought (e.g. participant and intervention characteristics, funding sources). Describe any assumptions made about any missing or unclear information.	18
Study risk of bias assessment	11	Specify the methods used to assess risk of bias in the included studies, including details of the tool(s) used, how many reviewers assessed each study and whether they worked independently, and if applicable, details of automation tools used in the process.	18
Effect measures	12	Specify for each outcome the effect measure(s) (e.g. risk ratio, mean difference) used in the synthesis or presentation of results.	-
Synthesis methods	13a	Describe the processes used to decide which studies were eligible for each synthesis (e.g. tabulating the study intervention characteristics and comparing against the planned groups for each synthesis (item #5)).	-
	13b	Describe any methods required to prepare the data for presentation or synthesis, such as handling of missing summary statistics, or data conversions.	-
	13c	Describe any methods used to tabulate or visually display results of individual studies and syntheses.	-
	13d	Describe any methods used to synthesize results and provide a rationale for the choice(s). If meta-analysis was performed, describe the model(s), method(s) to identify the presence and extent of statistical heterogeneity, and software package(s) used.	-
	13e	Describe any methods used to explore possible causes of heterogeneity among study results (e.g. subgroup analysis, meta-regression).	-
	13f	Describe any sensitivity analyses conducted to assess robustness of the synthesized results.	-
Reporting bias assessment	14	Describe any methods used to assess risk of bias due to missing results in a synthesis (arising from reporting biases).	-

Section and Topic	Item #	Checklist item	Location where item is reported
Certainty assessment	15	Describe any methods used to assess certainty (or confidence) in the body of evidence for an outcome.	-
RESULTS			
Study selection	16a	Describe the results of the search and selection process, from the number of records identified in the search to the number of studies included in the review, ideally using a flow diagram.	19
	16b	Cite studies that might appear to meet the inclusion criteria, but which were excluded, and explain why they were excluded.	21
Study characteristics	17	Cite each included study and present its characteristics.	24
Risk of bias in studies	18	Present assessments of risk of bias for each included study.	25
Results of individual studies	19	For all outcomes, present, for each study: (a) summary statistics for each group (where appropriate) and (b) an effect estimate and its precision (e.g. confidence/credible interval), ideally using structured tables or plots.	27-32
Results of syntheses	20a	For each synthesis, briefly summarise the characteristics and risk of bias among contributing studies.	-
	20b	Present results of all statistical syntheses conducted. If meta-analysis was done, present for each the summary estimate and its precision (e.g. confidence/credible interval) and measures of statistical heterogeneity. If comparing groups, describe the direction of the effect.	-
	20c	Present results of all investigations of possible causes of heterogeneity among study results.	-
	20d	Present results of all sensitivity analyses conducted to assess the robustness of the synthesized results.	-
Reporting biases	21	Present assessments of risk of bias due to missing results (arising from reporting biases) for each synthesis assessed.	-
Certainty of evidence	22	Present assessments of certainty (or confidence) in the body of evidence for each outcome assessed.	-
DISCUSSION			
Discussion	23a	Provide a general interpretation of the results in the context of other evidence.	33
	23b	Discuss any limitations of the evidence included in the review.	38
	23c	Discuss any limitations of the review processes used.	37
	23d	Discuss implications of the results for practice, policy, and future research.	38
OTHER INFORMATION			
Registration and protocol	24a	Provide registration information for the review, including register name and registration number, or state that the review was not registered.	-
	24b	Indicate where the review protocol can be accessed, or state that a protocol was not prepared.	-
	24c	Describe and explain any amendments to information provided at registration or in the protocol.	-
Support	25	Describe sources of financial or non-financial support for the review, and the role of the funders or sponsors in the review.	-
Competing interests	26	Declare any competing interests of review authors.	-
Availability of data, code and other	27	Report which of the following are publicly available and where they can be found: template data collection forms; data extracted from included studies; data used for all analyses; analytic code; any	-

Section and Topic	Item #	Checklist item	Location where item is reported
materials		other materials used in the review.	

**Transcrestal sinus floor elevation with or without bone graft: a
systematic review**

Matteo Nardinelli¹, Alberto Molina Palomero², María Gracia Sarrión Pérez³

¹ Universidad Europea de Valencia. Faculty of Health Sciences. Department of Dentistry

² Professor, Universidad Europea de Valencia. Faculty of Health Sciences. Department of Dentistry

³ Professor, Universidad Europea de Valencia. Faculty of Health Sciences. Department of Dentistry

Address for correspondance:

Via Ronciglione 15, 00191 Rome, Italy

+39 3271253425

matteonardinelli98@gmail.com

Objectives: The aim of this study was to determine the differences in endosinus bone gain in height, marginal bone loss, complications, the survival rate and patient satisfaction of the implants placed using transcresal sinus floor elevation with and without bone graft, with a minimum follow up of 6 months after surgery. **Materials and methods:** An electronic and manual search were conducted to retrieve clinical studies on indirect sinus floor elevation with or without graft. The electronic search was performed on three online databases: PubMed/MEDLINE, Scopus, and Web of Science from January 2012 to January 2022, relevant studies were selected according to the inclusion criteria. **Results:** 8 articles were selected and a total of 366 implants were studied, of which 228 were placed with a graft biomaterial and 138 without any bone graft biomaterial. Within a follow up from 24 to 120 months the survival rate was 96.7% for the grafted group and 97.2% for the group without graft. There was no significant difference in endosinus bone gain, marginal bone loss after a period of three years between the grafted and non-grafted implants. The complications found were not related to the insertion or not of a grafting material. **Conclusions:** Sinus augmentation via indirect access is a safe and predictable technique and its prognostic does not change when bone graft material is not used. **Keywords:** transcresal sinus elevation; indirect sinus floor augmentation; sinus lift with bone graft; graft-less sinus lift; osteotome technique; maxillary sinus; bone regeneration.

INTRODUCTION

Replacing one or more missing teeth with dental implants is a good treatment option with a high success rate (1–3). However, the region of the posterior maxilla is often limited for standard implant placement since the alveolar bone height is substantially reduced because of the presence and pneumatization of the maxillary sinus, and this can lead to a situation where dental implants can not be placed (1,2). The maxillary sinuses (MS) are the largest of the paranasal sinuses, having an average volume of 12,5mL (4). Its walls are lined by the Schneiderian membrane, which is a thin bilateral mucoperiosteal membrane: the side facing the lumen of the sinus is comprised of pseudostratified columnar epithelium whereas the bone side is comprised of an osteogenic periosteal layer (5) which contains stem cells, and it is thought to be important in the healing of bone grafts. Commonly, with ageing the sinus can expand and result in less bone in the posterior maxilla, this process is known as sinus pneumatization (6,7). Furthermore, posterior maxillary teeth extraction or absence can cause alveolar ridge remodeling, which can result in a downward expansion of the maxillary sinus. From a clinical point of view, maxillary sinus pneumatization and ridge resorption in the coronal area of the

extraction socket can reduce the available bone height for future implant insertion (8,9), and therefore a sinus lift surgery is needed. The maxillary sinus lift surgery was first described and published in 1980 by Boyne and James (10), it consisted in opening a lateral window on the maxillary bone to access directly the sinus and lift the membrane. In 1994 Summers (11) proposed a more conservative approach: the transcrestal sinus floor elevation (TSFE). The technique consisted in using a set of tapered osteotomes of increasing diameter to elevate the floor of the sinus, this is commonly referred to as the “osteotome technique” or “Summers technique”. This approach can be considered less traumatic and more conservative than the lateral window access but can be used only if the patient has adequate bone height. However, due to the exceptionally good healing capacity of the chamber created below the Schneiderian membrane when an implant is placed inside the sinus (12–14), the need for addition of a graft material is questionable. This raises the need to clarify the differences in endosinus bone gain, marginal bone loss, complications, survival rate and even the patient perspective of the implants placed using transcrestal sinus floor elevation with and without bone graft.

MATERIALS AND METHODS

This systematic review was conducted in complete accordance with the guidelines of the Preferred Reporting of Systematic Reviews and Meta-analyses (PRISMA) statement (15). The protocol of this review was registered in the International Prospective Register for Systematic Reviews (PROSPERO). Clinical questions were separated and organized using the P.I.C.O. strategy. Is the indirect sinus lift technique, without the use of bone graft material, a valid technique to treat with implants atrophic posterior maxillae when compared with transcrestal technique with bone graft in the same category of patients?

The inclusion criteria were: articles in English, Spanish and Italian, clinical trials, studies that analyzed the amount of bone formation after indirect maxillary sinus lift with and without the use of bone graft material reporting detailed information with a minimum follow-up of 6 months

The exclusion criteria were: systematic reviews, meta-analysis, literature reviews, and letters to the editor, case reports, case series with less than 10 cases, animal studies, studies involving volunteers with decompensated metabolic diseases or involving participants aged < 18 years old

Search strategy and sources of data: Relevant studies were identified through three online databases: PubMed/ MEDLINE, Scopus, and Web of Science. The last search was conducted in January of 2022 in the three databases mentioned. The following search strategy

was used: ("Sinus Floor Augmentation" [Mesh] OR "sinus lift" OR "sinus augmentation" OR "sinus elevation" OR "osteotome technique" OR "sinus graft" OR "sinus floor elevation" OR "sinus floor lift") AND ("indirect" OR "transcrestal" OR "transalveolar" OR "osteotome" OR "bone graft*" OR "graft*" OR "bone augmentation" OR "graft-free" OR "non-graft*") AND ("dental implants").

Screening for article selection: Titles and abstracts of all the references obtained through the last search on the electronic databases were examined independently and blindly by two reviewers (M.N. and A.B.) who selected for the analysis of the full text the studies that complied with the inclusion criteria or the ones with insufficient data to make a decisive exclusion. The disagreement regarding inclusion or exclusion was solved through a third reviewer (A. M. P.). After the initial selection, the reviewers read independently and blindly the full text of the selected articles. To complement the databases search, cross-searching of cited references in the studies that were eligible after the full-text screening was performed. A manual search was also carried out in the following international journals: Implant dentistry, International Journal of Implant Dentistry, Journal of Clinical Experimental Dentistry, Journal of Periodontology, Journal of Oral Implantology, Periodontology 2000, and Clinical Oral Implants Research from January 2012 till January 2022.

Risk of bias assessment: The risk of bias was analyzed by the author (M.N.) for each of the articles selected. The Cochrane Risk of Bias Tool for randomized controlled trials (16) and ROBINS-I risk of bias tool to assess non-randomized studies of interventions (17) were used. The risk was classified as low, unclear, or high.

Data extraction: The data extraction of the selected references was performed by the author. The following data were identified and extracted: First author, year, type of study, number of patients, age, gender, number at start, number at end, use of bone graft, implant diameter, implant length, number of sinuses elevated, implant site, make of implant, implant number, biomaterial used, preoperative residual bone height, endosinus bone gain, implant protrusion length, follow up, survival rate, marginal bone loss, complications, patient satisfaction, number of patients who smoke.

RESULTS

The search yielded a total of 2292 records, of which 704 were from PubMed, 546 from Scopus, and 1042 from Web of Science. The duplicates were removed, and a total of 1184 records were screened

by title and abstract. After the screening process, 95 registers were selected for full-text retrieval and assessment according to eligibility criteria. A total of 6 articles met our inclusion criteria.

The cross-searching of cited references in the studies that were eligible revealed one potential record which was then included in the screening process and later included in this review. The manual search which was carried out in the international journals mentioned previously yielded one record that met our inclusion criteria, and it was included in this review. A total of 8 articles were included in this systematic review. Cohen's kappa coefficient to measure inter-examiner agreement was calculated ($K=0.91$) for the analysis of the full text. Image 1 represents this process using the PRISMA flow diagram (15). Of the eight studies included studies, 6 were Randomized clinical trials (RCT) (18–23) and 2 were non-randomized studies of intervention (24,25). In three studies (18,20,23) some patients suffered perforation of the Schneiderian membrane, and they were excluded from the studies. The studies investigated the endosinus bone gain (EBG) (18–25), the marginal bone loss (MBL) (18–21,24), survival rate (18–21,23,24), complications (18–24) and patient satisfaction (19) for TSFE with and without bone graft. Data was gathered about 366 implants, of which 228 were placed with a graft biomaterial and 138 without any bone graft biomaterial. The follow up of the studies ranged from the immediate postoperative to 120 months. Five articles (18–21) in this systematic review used the implant success criteria by Buser et al. (26) and Cochran et al. (27), two articles (22,25) did not report success rate, and another one used the implant success criteria by Karoussis (28).

The sites that received 228 implants together with bone grafts, had a residual bone height that ranged from 1.4 mm to 7.04 mm, the diameter of the implants placed ranged from 4.1 mm to 5 mm and their length from 6 mm to 11.5 mm. The highest success rate was 100% and the lowest 90%, with an average of 96.7%. The most common complications reported were periimplantitis (18,20), and mobility, which was reported in one article (21) and failure due to marginal bone loss (20). One implant out of 228 failed due to periimplantitis at 6-12 months follow up, one due to mobility at 1.8 months, and one due to marginal bone loss. The weighted average of preoperative residual bone heights of all studies except two, which did not report it, (22,25) was 5.72 mm.

The sites that did not receive any type of bone graft material had ridges of residual bone heights that ranged from 1.7 mm to 7.04 mm, the diameter of the 138 implants ranged between 4,1 mm and 5 mm, and their length between 6 mm and 11.5 mm. The success rate ranged from 94.1% to 100%, with an average of and the most reported complication was periimplantitis. The most common

complication was periimplantitis (19,20). Two implants out of 138 were lost due to periimplantitis, one at 6-12 months follow up and another one at 32.4 months. The weighted average of preoperative residual bone heights of all studies except two, which did not report it, (22,25) was 5,15 mm.

Within a follow up from 24 to 120 months the average survival rate was 96.7% for the grafted group and 97.2% for the group without graft.

Results of risk of bias assessment: *RCTs*: Three (18,20) out of the six RCTs were considered as low overall risk of bias. The randomization process was well defined in all the studies, but in some (19,21,23), the bias due to deviations from intended interventions raised some concerns as it was not mentioned whether if the patients were aware of the treatment option that they received, and for two studies (19,21) the person delivering the intervention was the same that analyzed the outcomes. Measurement of the outcome and selection of the reported result were low for all the studies (Image 2). *Non-Randomized studies*: Both studies (24,25) raised some concerns for bias in measurement of outcomes, as one (24) did not mention the grade of knowledge about the intervention received by the patients, and the other one (25) did not mention whether if the assessors were aware or not of the intervention received by participants. Additionally, one (24) raised some concerns for bias due to confounding, because the graftless group received more short implants than the other group (Image 3).

DISCUSSION

Notably, the studies showed no significant difference or advantage between the implants placed with or without bone graft, confirmed by the fact that the survival rate was similar between the two groups: within a follow up from 24 to 120 months the survival rate was 96.7% for the grafted group and 97.2% for the group without graft. However, a difference existed when comparing the EBG, resulting slightly higher in the graft groups in the first 3 years, after 3 years the EBG measures tended to similar values in both groups. MBL resulted in similar values in both groups. The degree of patient satisfaction could not be assessed, as only one study reported it (19). In other words, the overall results showed concordance over changes of the variables analyzed. However, even if some variables in different studies had higher or lower values when compared to the overall mean, or were registered in different units of measure, they still did show concordance in proportion. Three implants failed in the groups with bone graft and two in the groups without bone graft, but the use or not of the grafting material had no significant influence on the prognosis of the implants. The weighted average of EBG

and MBL of autogenous + Bio-Oss® shows an important difference if compared to the Bio-Oss® alone, probably because a smaller sample was analyzed, as only one study (18,20) used the mix, and the pool of patients that received Bio-Oss® was almost double the size. Moreover, the Bio-Oss® group values were obtained from a mean between 3 studies (19,24,25). Interestingly the weighted average of the EBG at 60 months for the group augmented with Bio-Oss® resulted in higher values when compared at 6 and 12 months, this can be explained because one study reported a mean of EBG at 60 months and used longer implants in comparison to the other studies.

This review reported that a significant factor which influences new bone formation inside the sinus, and therefore enhances EBG, is the extension in which the implants protrude inside the sinus. This factor alone, if an adequate primary stability is achieved, can enhance the formation of new bone, possibly because of the tenting effect. This effect is the result of the elevation of the Schneiderian membrane, which is sustained by the apex of the implant protruding inside the sinus, the more the implant protrudes, the more its apex elevates the membrane. Dragonas (2020) (29) conducted a systematic review to analyze the potential of osteogenicity of the sinus membrane and concluded that the membrane contains pluripotent mesenchymal cells capable of differentiation and apport new bone formation, such findings reinforce the theory of periosteal-guided bone regeneration, which should not be underestimated or overlooked if there is the need to perform a successful and minimally invasive TSFE, since the tent formed by the membrane is stable and capable of maintaining space for the basic osteointegration process. Moreover, a relevant finding that confirmed a strong correlation between the tenting effect and EBG was published by Song (2020) (30) who placed 49 implants without bone graft in atrophic maxillae and studied the tenting effect obtained by lifting the membrane and placing an implant to sustain it. New bone formation was a constant finding at all sites after 6 months, and the amount of bone formation increased proportionally to the length of the implants in the sinus. This review showed that not only the new bone formation occurred in both groups in the short term, but also that after approximately three years the patients that received bone grafts reported a similar EBG compared to the patients that did not receive any graft, without any change regarding implant success. This is in line with the findings in the literature, as Kim (2014) (31) investigated the resorption of different bone grafts in the maxillary sinus 3 years after implant placement and found no difference in shrinkage due to resorption between graft or technique used, meaning that graft materials undergo inevitable shrinkage, eventually stabilize and reaches similar dimensions as

graftless placed implants. Another outcome of interest for this review was the marginal bone loss, which was found to be similar in both groups after a three-year period at every follow up. Mainly the most MBL found in patients was associated to periodontitis and not to the grafting technique which was used. In concordance with these results, Fermergård (2012) (32) conducted a three-year retrospective study on 53 implants placed using TSFE without bone graft in 36 patients and found that the marginal bone loss had not changed significantly after three years, this is concordant to the outcome of this review, moreover they also found predictable results in terms of clinical success, comparable to grafted implants. No complications were related to the insertion or not of bone graft in the sinus. Furthermore, the survival rate was not influenced by the grafting technique used. The most frequently related complications were periodontitis, as some patients in the studies were ex-periodontal patients, and mobility due to the lack of primary stability, since the review pooled a significant number of extremely atrophic sites, but no relevant complication appeared because of the grafting technique. A similar systematic review to this one was conducted by Silva (2016) (33), a meta-analysis was also performed, 667 implants installed in the maxillary sinuses with biomaterial and 201 with only the clot were analyzed. The authors only studied the survival rate and complications but did not encounter statistically significant difference for these variables between the two groups, reinforcing the validity of the findings of this review about the lack of connection between complications and lower survival rates associated with the interposition or not of bone graft in TSFE. The limitations of this review were that three databases were used for the electronic research, and only articles written in english, italian and spanish language. Also, a smaller number of implants than expected was analyzed, the graftless sample had less implants than the garfted sample. More limitations raised because articles such as the ones published by Nedir et al. (2013) (21) and Nedir et al. (2017) (19), or the articles by Si et al. (18) and Quian et al., were analyzing the same sample of patients which received TSFE with or without bone graft. However, they both had to be included in this review as they reported data at different follow up times, and the information of one article complemented the other. When analyzing the results, they were considered as one complete study without counting the double amount of data. Another limitation was that not all the studies included used the same unit of measure to record their data, one study (23) measured EBG in cubic centimeters instead of millimeters, therefore it could not be directly compared with the rest of the studies. Nevertheless, this review had interesting outcomes that should be considered when operating

clinically, oral and maxillofacial surgeons should be aware that graft material could not be needed to increase the clinical success of implants placed using TSFE technique, if an adequate primary stability is achieved. The real need of the insertion of graft material along with TSFE should be questioned. It would be important for future investigators to be able to study a larger sample of implants placed with TSFE with or without bone graft since this study had the limitation of a relatively small sample. Also, future investigators should consider if the degree of patient satisfaction changes or not when the bone graft is avoided, since not enough evidence was found in order to determine this outcome. It can be concluded that in the first year after placement, the grafted implants reported moderately higher values of endosinus bone gain compared to the non-grafted implants. In the first year after location of the implants the marginal bone loss was found to be slightly higher in non-grafted implants. After a period of three years, both values of endosinus bone gain and marginal bone loss resulted similar, regardless of the grafting technique. No complications were associated to the grafting technique and no significant differences in terms of implant survival rate were found between the implants placed with or without bone graft.

Conflicts of interest: the authors have no conflict of interest to declare.

REFERENCES

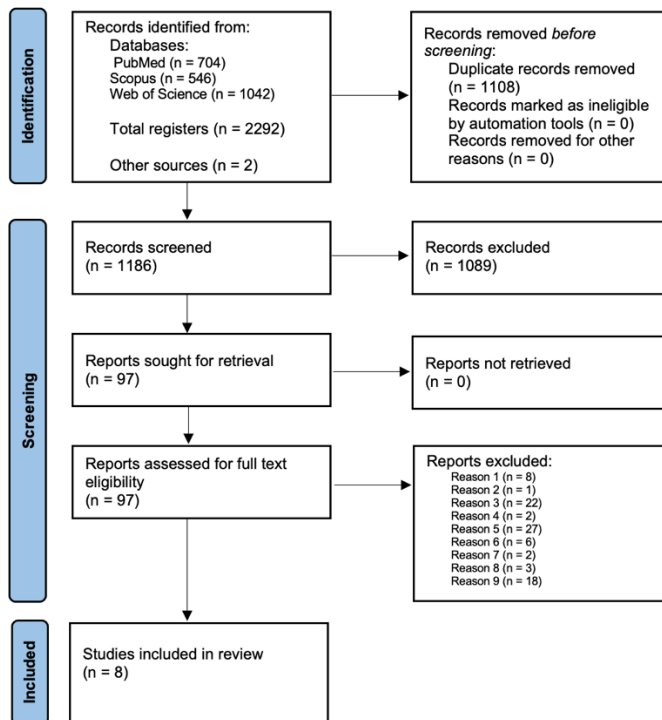
1. Pjetursson BE, Lang NP. Sinus floor elevation utilizing the transalveolar approach. *Periodontol 2000*. 2014 Oct;66(1):59–71.
2. Lundgren S, Cricchio G, Hallman M, Jungner M, Rasmusson L, Sennerby L. Sinus floor elevation procedures to enable implant placement and integration: techniques, biological aspects and clinical outcomes. *Periodontol 2000*. 2017 Feb 1;73(1):103–20.
3. Stern A, Green J. Sinus Lift Procedures: An Overview of Current Techniques. *Dental Clinics of North America*. 2012;56(1):219–33.
4. Gosau M, Rink D, Driemel O, Draenert FG. Maxillary sinus anatomy: a cadaveric study with clinical implications. *Anat Rec (Hoboken)*. 2009 Mar;292(3):352–4.
5. Molvaer OI, Vallersnes FM, Kringlebotn M. The size of the middle ear and the mastoid air cell. *Acta Otolaryngol*. 1978;85(1–2):24–32.
6. Lim HC, Kim S, Kim DH, Herr Y, Chung JH, Shin S il. Factors affecting maxillary sinus pneumatization following posterior maxillary tooth extraction. *J Periodontal Implant Sci*. 2021 Aug;51(4):285–95.

7. Jun BC, Song SW, Park CS, Lee DH, Cho KJ, Cho JH. The analysis of maxillary sinus aeration according to aging process; volume assessment by 3-dimensional reconstruction by high-resolution CT scanning. *Otolaryngology--head and neck surgery : official journal of American Academy of Otolaryngology-Head and Neck Surgery*. 2005 Mar;132(3):429–34.
8. Farina R, Pramstraller M, Franceschetti G, Pramstraller C, Trombelli L. Alveolar ridge dimensions in maxillary posterior sextants: a retrospective comparative study of dentate and edentulous sites using computerized tomography data. *Clin Oral Implants Res*. 2011 Oct;22(10):1138–44.
9. Levi I, Halperin-Sternfeld M, Horwitz J, Zigdon-Giladi H, Machtei EE. Dimensional changes of the maxillary sinus following tooth extraction in the posterior maxilla with and without socket preservation. *Clin Implant Dent Relat Res*. 2017 Oct;19(5):952–8.
10. Boyne PJ, James RA. Grafting of the maxillary sinus floor with autogenous marrow and bone. *J Oral Surg*. 1980 Aug;38(8):613–6.
11. Summers RB. A new concept in maxillary implant surgery: the osteotome technique. *Compendium*. 1994 Feb;15(2):152, 154–6, 158 passim; quiz 162.
12. Volpe S, Colasanti U, Pagliani L. Coagulo e membrana sinusale: connubio ideale per la rigenerazione ossea all'interno dei seni mascellari. *Dent Cadmos*. 2016;84(5):282–90.
13. Qabbani A al, Bayatti SW al, Hasan H, Samsudin AB, Kawas S al. Clinical and Radiological Evaluation of Sinus Membrane Osteogenicity Subsequent to Internal Sinus Lifting and Implant Placement. *J Craniofac Surg*. 2020;31(3):e233–6.
14. Lie N, Merten HA, Meyns J, Lethaus B, Wiltfang J, Kessler P. Elevation of the maxillary sinus membrane for de-novo bone formation: First results of a prospective study in humans. *Journal of cranio-maxillo-facial surgery : official publication of the European Association for Cranio-Maxillo-Facial Surgery*. 2015 Oct;43(8):1670–7.
15. Page MJ, McKenzie JE, Bossuyt PM, Boutron I, Hoffmann TC, Mulrow CD, et al. The PRISMA 2020 statement: an updated guideline for reporting systematic reviews. *BMJ*. 2021 Mar;372:n71.
16. Sterne JAC, Savović J, Page MJ, Elbers RG, Blencowe NS, Boutron I, et al. RoB 2: a revised tool for assessing risk of bias in randomised trials. *BMJ*. 2019 Aug;366:l4898.

17. Sterne JA, Hernán MA, Reeves BC, Savović J, Berkman ND, Viswanathan M, et al. ROBINS-I: a tool for assessing risk of bias in non-randomised studies of interventions. *BMJ*. 2016 Oct;355:i4919.
18. Si MS, Zhuang LF, Gu YX, Mo JJ, Qiao SC, Lai HC. Osteotome sinus floor elevation with or without grafting: A 3-year randomized controlled clinical trial. *Journal of Clinical Periodontology*. 2013;40(4):396–403.
19. Nedir R, Nurdin N, Abi Najm S, el Hage M, Bischof M. Short implants placed with or without grafting into atrophic sinuses: the 5-year results of a prospective randomized controlled study. *Clin Oral Implants Res*. 2017 Jul;28(7):877–86.
20. Qian SJ, Mo JJ, Si MS, Qiao SC, Shi JY, Lai HC. Long-term outcomes of osteotome sinus floor elevation with or without bone grafting: The 10-year results of a randomized controlled trial. *J Clin Periodontol*. 2020 Aug;47(8):1016–25.
21. Nedir R, Nurdin N, Khoury P, Perneger T, Hage M el, Bernard JP, et al. Osteotome sinus floor elevation with and without grafting material in the severely atrophic maxilla. A 1-year prospective randomized controlled study. *Clin Oral Implants Res*. 2013 Nov;24(11):1257–64.
22. Trinh HA, Dam VV, Le B, Pittayapat P, Thunyakitpisal P. Indirect Sinus Augmentation With and Without the Addition of a Biomaterial: A Randomized Controlled Clinical Trial. *Implant Dent*. 2019 Dec;28(6):571–7.
23. Marković A, Mišić T, Calvo-Guirado JL, Delgado-Ruiz RA, Janjić B, Abboud M. Two-Center Prospective, Randomized, Clinical, and Radiographic Study Comparing Osteotome Sinus Floor Elevation with or without Bone Graft and Simultaneous Implant Placement. *Clin Implant Dent Relat Res*. 2016 Oct;18(5):873–82.
24. Verdugo F, Uribarri A, Laksmana T, D’addona A. Long-term stable vertical bone regeneration after sinus floor elevation and simultaneous implant placement with and without grafting. *Clin Implant Dent Relat Res*. 2017 Dec;19(6):1054–60.
25. Yang J, Xia T, Fang J, Shi B. Radiological Changes Associated with New Bone Formation Following Osteotome Sinus Floor Elevation (OSFE): A Retrospective Study of 40 Patients with 18-Month Follow-Up. *Medical science monitor : international medical journal of experimental and clinical research*. 2018 Jul;24:4641–8.

26. Buser D, Mericske-Stern R, Bernard JP, Behneke A, Behneke N, Hirt HP, et al. Long-term evaluation of non-submerged ITI implants. Part 1: 8-year life table analysis of a prospective multi-center study with 2359 implants. *Clin Oral Implants Res.* 1997 Jun;8(3):161–72.
27. Cochran DL, Buser D, ten Bruggenkate CM, Weingart D, Taylor TM, Bernard JP, et al. The use of reduced healing times on ITI implants with a sandblasted and acid-etched (SLA) surface: early results from clinical trials on ITI SLA implants. *Clin Oral Implants Res.* 2002 Apr;13(2):144–53.
28. Karoussis IK, Brägger U, Salvi GE, Bürgin W, Lang NP. Effect of implant design on survival and success rates of titanium oral implants: a 10-year prospective cohort study of the ITI Dental Implant System. *Clin Oral Implants Res.* 2004 Feb;15(1):8–17.
29. Dragonas P, Katsaros T, Schiavo J, Galindo-Moreno P, Avila-Ortiz G. Osteogenic capacity of the sinus membrane following maxillary sinus augmentation procedures: A systematic review. *Int J Oral Implantol (Berl).* 2020;13(3):213–32.
30. Song DS, Kim CH, Kim BJ, Kim JH. Tenting effect of dental implant on maxillary sinus lift without grafting. *J Dent Sci.* 2020 Sep;15(3):278–85.
31. Kim YK, Kim SG, Kim BS, Jeong KI. Resorption of bone graft after maxillary sinus grafting and simultaneous implant placement. *J Korean Assoc Oral Maxillofac Surg.* 2014 Jun;40(3):117–22.
32. Fermergård R, Åstrand P. Osteotome sinus floor elevation without bone grafts--a 3-year retrospective study with Astra Tech implants. *Clin Implant Dent Relat Res.* 2012 Apr;14(2):198–205.
33. Silva L de F, de Lima VN, Faverani LP, de Mendonça MR, Okamoto R, Pellizzer EP. Maxillary sinus lift surgery-with or without graft material? A systematic review. *Int J Oral Maxillofac Surg.* 2016 Dec;45(12):1570–6.

Figures of the article



	D1	D2	D3	D4	D5	Overall	
Si et al. (151)	+	+	+	+	+	+	Low risk
Quian et al. (153)	+	+	+	+	+	+	Low risk
Nedir et al. (154)	+	!	+	+	+	!	Some concerns
Nedir et al. (152)	+	!	+	+	+	!	Some concerns
Trinh et al. (155)	+	+	+	+	+	!	Some concerns
Markovic et al. (156)	+	!	+	+	+	!	Some concerns

+ Low risk
 ! Some concerns
 - High risk

D1 Randomisation process
 D2 Deviations from the intended interventions
 D3 Missing outcome data
 D4 Measurement of the outcome
 D5 Selection of the reported result

	D1	D2	D3	D4	D5	D6	D7	Overall	
Verdugo et al. (157)	!	+	+	+	+	!	+	!	Some concerns
Yang et al. (158)	+	+	+	+	+	!	+	!	Some concerns

+ Low risk
 ! Some concerns
 - High risk

D1 Bias due to confounding
 D2 Bias in selection of participants into the study
 D3 Bias in classification of interventions
 D4 Bias due to deviations from intended interventions
 D5 Bias due to missing data
 D6 Bias in measurement of outcomes
 D7 Bias in selection of the reported result

Tables of the article

Table 1. Information about materials used. NR: not reported

Author	Use of Graft Yes: 1 No: 0	Implant diameter				Implant length				Number of sinuses elevated	Implant site		Make of implants	Number of implants	Biomaterial used
		4.1 mm	4.5 mm	4.8 mm	5 mm	6 mm	8 mm	10 mm	11.5 mm		Premolar	Molar			
Si et al. (18)	1	11	--	10	--	3	8	10	--	NR	7	14	Straumann*	21	Autogenous bone mixed with Bio-Oss*
	0	8	--	12	--	2	9	9	--	NR	9	11		20	None
Quian et al. (20)	1	NR	NR	NR	NR	3	8	10	--	21	7	14	Straumann*	21	Autogenous bone mixed with Bio-Oss*
	0	NR	NR	NR	NR	2	8	9	--	19	9	11		19	None
Verdugo et al. (24)	1	9	--	7	--	2	8	6	6	NR	7	9	Biomet 3i* Osseotite*	16	Bio-Oss*
	0	5	--	9	--	7	4	3	NR	4	10	10		14	None
Nedir et al. (21)	1	NR	NR	NR	NR	--	20	--	--	10	5	32	Straumann*	18	Bio-Oss*
	0	NR	NR	NR	NR	--	17	--	--	9	--	--		17	None
Nedir et al. (19)	1	NR	--	NR	--	--	20	--	--	10	5	32	Straumann*	18	Bio-Oss*
	0	NR	--	NR	--	--	17	--	--	9	--	--		16	None
Yang et al. (25)	1	--	20	--	31	45	6	--	--	NR	NR	NR	Bicon*	24	Bio-Oss*
	0	--	--	--	--	--	--	--	--	NR	NR	NR		27	None
Trinh et al. (22)	1	--	--	--	--	--	--	--	14	NR	NR	NR	Osstem Implant*	14	50 mg Acemann* sponge
	0	--	--	--	--	--	--	--	15	NR	NR	NR		15	None
Marković et al. (23)	1	--	--	--	--	--	--	--	--	NR	NR	NR	Straumann*	45	BoneCeramic*
	1	180	--	--	--	--	--	--	--	NR	NR	NR		45	Bio-Oss*
	1	--	--	--	--	--	--	--	--	NR	NR	NR		45	BoneCeramic* + Bio-Oss*
	0	--	--	--	--	--	--	--	--	NR	NR	NR		45	None

Table 2. Information about EBG, implant protrusion length, follow up and survival rate. NR: not reported

Author	Use of Graft Yes: 1 No: 0	Pre-operative residual bone height (mm)	Endosinus bone gain (mm) (±7m)								Implant protrusion length	Follow up total	Survival rate	
			Post-operative	6 m	12 m	18 m	24 m	36 m	60 m	120 m				
Si et al. (18)	1	4.67 ± 1.18	--	5.66 ± 0.99	3.56 ± 1.82	--	3.02 ± 0.48	3.17 ± 1.95	--	--	3.75 ± 1.43	6-12-24-36 months	95.2%	
	0	4.58 ± 1.47	--	2.06 ± 1.01	2.45 ± 0.98	--	3.12 ± 0.70	3.07 ± 1.68	--	--	3.94 ± 1.63			95.0%
Quian et al. (20)	1	4.67 ± 1.18	--	--	3.56 ± 1.82	--	--	3.17 ± 1.95	3.03 ± 1.61	3.07 ± 1.34	3.75 ± 1.43	12-36-60- 120 months	90.7%	
	0	4.58 ± 1.47	--	--	2.45 ± 0.98	--	--	3.07 ± 1.68	3.12 ± 1.31	3.14 ± 1.26	3.94 ± 1.63			95.0%
Verdugo et al. (24)	1	3.8 ± 1.2	--	--	--	--	--	--	8.5 ± 1.9	--	NR	64.6 months	100%	
	0	4.5 ± 0.8	--	--	--	--	--	--	6.8 ± 0.5	--	NR			100%
Nedir et al. (21)	1	2.2 ± 0.8	--	--	5.0 ± 1.3	--	--	--	--	--	--	12 months	90%	
	0	2.6 ± 0.9	--	--	3.9 ± 1.0	--	--	--	--	--	5.0 ± 1.2			100%
Nedir et al. (19)	1	2.2 ± 0.8	--	--	5.0 ± 1.3	--	--	5.1 ± 1.2	4.8 ± 1.2	--	--	60 months	90.0%	
	0	2.6 ± 0.9	--	--	3.9 ± 1.0	--	--	4.1 ± 1.0	3.8 ± 1.0	--	5.0 ± 1.2			94.1%
Yang et al. (25)	1	NR	4.63 ± 2.35	4.28 ± 2.37	4.09 ± 2.38	3.96 ± 2.38	--	--	--	--	1.80 ± 1.37	18 months	NR	
	0	NR	1.24 ± 1.80	1.36 ± 1.37	1.33 ± 1.22	1.29 ± 1.07	--	--	--	--	1.26 ± 0.77			NR
Trinh et al. (22)	1	NR	6.7 ± 0.3	3.2 ± 0.3	--	--	--	--	--	--	NR	6 months	NR	
	0	NR	6.7 ± 0.2	1.6 ± 0.3	--	--	--	--	--	--	NR			NR
Marković et al. (23)	1	--	--	0.59 cc	0.28 cc	--	0.23 cc	--	--	--	NR	24 months	100%	
	1	6.59 ± 0.45	--	0.34 cc	0.19 cc	--	0.12 cc	--	--	--	NR			100%
	1	--	--	0.34 cc	0.29 cc	--	0.24 cc	--	--	--	NR			100%
	0	--	--	0.43 cc	0.29 cc	--	0.22 cc	--	--	--	NR			100%

Table 3: Information about MBL, complications and patient satisfaction. NR: not reported

Author	Use of Graft Yes: 1 No: 0	Pre-operative residual bone height (mm)	Marginal bone loss (mm) (±7m)						Complications	Patient's satisfaction
			6 m	12 m	24 m	36 m	60 m	120 m		
Si et al. (18)	1	4.67 ± 1.18	0.21 ± 0.23	0.44 ± 0.16	0.65 ± 0.30	1.33 ± 0.46	--	--	One implant in both groups was lost after 6-12 m. of functional loading, due to peri-implantitis	NR
	0	4.58 ± 1.47	0.67 ± 0.98	1.28 ± 0.05	1.32 ± 0.45	1.38 ± 0.23	--	--		NR
Quian et al. (20)	1	4.67 ± 1.18	--	0.44 ± 0.16	--	1.33 ± 0.46	1.50 ± 0.96	1.67 ± 1.06	One 10 mm imp. failed after 6-12 m. follow-up. Another 8- mm imp. was lost after 6 y. loading due to marginal bone loss	NR
	0	4.58 ± 1.47	--	1.28 ± 0.05	--	1.38 ± 0.23	1.43 ± 0.76	1.52 ± 1.08		NR
Verdugo et al. (24)	1	3.8 ± 1.2	--	--	--	--	0.8 ± 0.7	--	Two implants developed 6 mm pockets	NR
	0	4.5 ± 0.8	--	--	--	--	0.9 ± 0.6	--		NR
Nedir et al. (21)	1	2.2 ± 0.8	--	0.4 ± 0.7	--	--	--	--	At 1.8 months, 2 impl. were mobile, appeared moved coronally, after removal, only one was later replaced w/o more graft	NR
	0	2.6 ± 0.9	--	0.6 ± 0.8	--	--	--	--		NR
Nedir et al. (19)	1	2.2 ± 0.8	--	0.4 ± 0.7	--	0.5 ± 1.0	0.7 ± 1.4	--	None	Complete satisfaction
	0	2.6 ± 0.9	--	0.6 ± 0.8	--	0.6 ± 1.1	0.6 ± 0.9	--		At 32.4 months one implant failed due to peri-implantitis
Yang et al. (25)	1	NR	NR	NR	NR	NR	NR	NR	NR	NR
	0	NR	NR	NR	NR	NR	NR	NR		NR
Trnir et al. (22)	1	NR	NR	NR	NR	NR	NR	NR	None	NR
	0	NR	NR	NR	NR	NR	NR	NR		NR
Marković et al. (23)	1	6.59 ± 0.45 (overall mean)	NR	NR	NR	NR	NR	NR	Sinus membrane perforation in 5 patients that were excluded from the study	NR
	1		NR	NR	NR	NR	NR	NR		NR
	1		NR	NR	NR	NR	NR	NR		NR
	0		NR	NR	NR	NR	NR	NR		NR

Table 4: reporting weighted averages of EBG and MBL

The weighted average of the endosinus bone gain (Autogenous + Bio-Oss® GRAFT) (mm)	The weighted average of the endosinus bone gain (Bio-Oss® GRAFT) (mm)	The weighted average of the endosinus bone gain (NO GRAFT) (mm)
5.66 at 6 months	4.28 at 6 months	1.64 at 6 months
3.56 at 12 months	4.48 at 12 months	2.36 at 12 months
3.03 at 60 months	6.54 at 60 months	4.39 at 60 months
The weighted average of the marginal bone loss (Autogenous + Bio-Oss® GRAFT) (mm)	The weighted average of the marginal bone loss (Bio-Oss® GRAFT) (mm)	The weighted average of the marginal bone loss (NO GRAFT) (mm)
0.44 at 12 months	0.4 at 12 months	0.96 at 12 months
1.33 at 36 months	0.5 at 36 months	1.03 at 36 months
1.50 at 60 months	0.74 at 60 months	1.00 at 60 months

Appendix 3

N°	Full-text analysis	Excluded: 0 Included: 5	Reason
96	Borges, F. L., Dias, R. O., Piattelli, A., Onuma, T., Gouveia Cardoso, L. A., Salomao, M., Scarano, A., Ayub, E., & Shibli, J. A. (2013). Simultaneous Sinus Membrane Elevation and Dental Implant Placement Without Bone Graft: A 6-Month Follow-Up Study. <i>JOURNAL OF PERIODONTICS</i> , 84(12), 402-412. https://doi.org/10.1002/jor.20100	0	Lateral technique
112	Cichocki, G., Semerly, L., & Lundgren, S. (2013). Sinus bone formation and implant survival after sinus membrane elevation and implant placement: a 1-to 6-year follow-up study. <i>CLINICAL ORAL IMPLANTS RESEARCH</i> , 22(10), 1200-1212. https://doi.org/10.1111/clor.12029	0	Only describes graftless technique
131	Ribeiro, C., & Ther, A. (2016). Follow-up of the Sinus Membrane Elevation Technique for Maxillary Sinus Implants without the Use of Graft Material. <i>CLINICAL IMPLANT DENTISTRY AND RELATED RESEARCH</i> , 18(5), 895-905. https://doi.org/10.1111/clir.12360	0	Lateral technique
185	Tomruk, C. O., Senoğlu, M. K., & Çapar, G. D. (2016). Prevalence of sinus floor elevation procedures and survival rates of implants placed in the posterior maxilla. <i>BIO TECHNOLOGY & BIOTECHNOLOGICAL EQUIPMENT</i> , 30(1), 134-139. https://doi.org/10.1080/13102818.2015.1102610	0	Review
187	Malchiodi, L., Cuchi, A., Ghensi, P., Caricassulo, R., & Nocini, P. F. (2016). The "Alternating Osteotome Technique": a surgical approach for combined ridge expansion and sinus floor elevation: A multicentre prospective study with a three-year follow-up. <i>BIO TECHNOLOGY & BIOTECHNOLOGICAL EQUIPMENT</i> , 30(4), 762-769. https://doi.org/10.1080/13102818.2016.1171732	0	Different objective
193	Lombardo, G., Marinazzo, M., Signoretto, A., Corrocher, G., & Nocini, P. F. (2020). Single-Crown, Short and Ultra-Short Implants, in Association with Simultaneous Sinus Floor Elevation in the Atrophic Posterior Maxilla: A Three-Year Retrospective Study. <i>MATERIALS</i> , 13(9). https://doi.org/10.3390/ma13092208	0	Different objective
203	Soydan, S. S., Cubuk, S., Bayrak, B., & Uckan, S. (2015). Comparative Evaluation of Simultaneous Maxillary Sinus Floor Elevation and Implant Placement with Residual Bone Heights Greater or Less than 5 mm. <i>INTERNATIONAL JOURNAL OF ORAL & MAXILLOFACIAL IMPLANTS</i> , 20(1), 179-183. https://doi.org/10.11607/jom.3634	0	Different objective
243	Lumbaa, A. I., Meloni, S. M., Tallarico, M., Melis, L., Spano, G., Baldoni, E., Koshovari, A., & Pisano, M. (2021). Implant Placement Following Great Sinus Lift with Sequential Drills and Osteotomes: Five Years After Final Loading Results from a Retrospective Study. <i>JOURNAL OF FUNCTIONAL BIOMATERIALS</i> , 12(11). https://doi.org/10.3390/f12110011	0	Different objective
334	Freiha, C., Kassar, A. R., Ghori, N., Mokbel, N., Naaman, N., & Dagher, M. (2021). Sub-antral volumetric variation after a modified trephine sinus elevation approach: An 8-month prospective study. <i>Journal of Osseointegration</i> , 11(1), 272-283. https://doi.org/10.1002/jos.1423	0	Different objective
383	Pabst, A. M., Walter, C., Eubaer, S., Zwerner, I., Ziebart, T., Al-Nawas, B., & Klein, M. O. (2015). Analysis of implant-failure predictors in the posterior maxilla: A retrospective study of 1395 implants. <i>Journal of Craniomaxillofacial Surgery</i> , 43(3), 454-460. https://doi.org/10.1016/j.jcms.2015.01.004	0	Review
406	Shi, J.-Y., Qian, S.-J., Gu, Y.-X., Qiao, S.-C., & Lai, H.-C. (2013). Osteotome sinus floor elevation with or without grafting: A 3-year randomized controlled clinical trial. <i>Journal of Clinical Periodontology</i> , 40(4), 396-403. https://doi.org/10.1111/jcpe.12066	1	
413	Mandelli, F., Ghensi, P., Vinci, R., & Mandelli, G. (2013). Sinus floor elevation with crestal apposition and immediately loaded post-retention implants. <i>Journal of Oral and Maxillofacial Surgery</i> , 71(1), 22-26. https://doi.org/10.1097/IDC.0b013e318276ad05e3	0	Case report
425	Zhen, F., Fang, W., Jing, S., & Zuo, W. (2012). The use of a piezoelectric ultrasonic osteotome for internal sinus elevation: A retrospective analysis of clinical results. <i>International Journal of Oral and Maxillofacial Implants</i> , 27(4), 920-926. https://doi.org/10.11607/jom.3634	0	Different objective
426	Benabou, T. (2021). Outcomes of flapless crestal maxillary sinus elevation under hydraulic pressure. <i>International Journal of Oral and Maxillofacial Implants</i> , 27(5), 1223-1229. https://doi.org/10.11607/jom.3634	0	Different objective
433	Bernardello, R., Righi, D., Cocci, F., Benazzi, P., Soledad, C., & Spinato, S. (2011). Crestal sinus lift with sequential drills and simultaneous implant placement in sites with <5 mm of native bone: A multicenter retrospective study. <i>Implant Dentistry</i> , 20(6), 439-444. https://doi.org/10.1097/ID.0b013e3182342052	0	Different objective
436	Baldi, D., Menini, M., Pera, F., Ravera, G., & Pera, P. (2011). Sinus floor elevation using osteotomes or piezoelectric surgery. <i>International Journal of Oral and Maxillofacial Surgery</i> , 40(5), 497-503. https://doi.org/10.1016/j.jcms.2011.01.008	0	Different objective
441	Mazor, Z., Kfir, E., Lorean, A., Mijinsky, E., & Horowitz, R. A. (2011). Flapless approach to maxillary sinus augmentation using minimally invasive antral membrane balloon elevation. <i>Implant Dentistry</i> , 20(6), 434-438. https://doi.org/10.1097/ID.0b013e3182342052	0	Different objective
463	Nizam, N., Gürlek, Ö., & Kaval, M. E. (2020). Extra-Short Implants with Osteotome Sinus Floor Elevation: A Prospective Clinical Study. <i>The International Journal of Oral & Maxillofacial Implants</i> , 35(2), 415-422. https://doi.org/10.11607/jom.3990	0	Different objective
466	Shi, J.-Y., Qian, S.-J., Gu, Y.-X., Qiao, S.-C., Tonetti, M. S., & Lai, H.-C. (2020). Long-term outcomes of osteotome sinus floor elevation without grafting in severely atrophic maxilla: A 10-year prospective study. <i>Journal of Clinical Periodontology</i> , 47(12), 1528-1535. https://doi.org/10.1111/jcpe.13365	0	Only describes graftless technique
471	Qian, S.-J., Mo, J.-J., Shi, M.-S., Qiao, S.-C., Shi, J.-Y., & Lai, H.-C. (2020). Long-term outcomes of osteotome sinus floor elevation with or without bone grafting: The 10-year results of a randomized controlled trial. <i>Journal of Clinical Periodontology</i> , 47(8), 1016-1025. https://doi.org/10.1111/jcpe.13260	1	
474	Rammelsberg, P., Pathe, J., Bischof, C., & Zenthofer, A. (2020). Long-term apical bone gain after implant placement combined with internal sinus floor elevation without graft. <i>BMC Oral Health</i> , 20(1), 197. https://doi.org/10.1186/s12903-020-01178-4	0	Only describes graftless technique
475	Shi, J.-Y., Li, Y., Qiao, S.-C., Gu, Y.-X., Xiong, Y.-Y., & Lai, H.-C. (2019). Short versus longer implants with osteotome sinus floor elevation for moderately atrophic posterior maxilla: A 1-year randomized clinical trial. <i>Journal of Clinical Periodontology</i> , 46(8), 855-862. https://doi.org/10.1111/jcpe.13147	0	Different objective
480	Nahlieli, O., Bolangui, A., Abramson, A., Abu, M., Nahlieli, D., & Srouji, S. (2019). Graftless sinus floor augmentation with an internal post implant: long-term experience. <i>Quintessence International (Berlin, Germany)</i> , 50(17), 560-567. https://doi.org/10.3290/j.issn.1600-0560.190117	0	Only describes graftless technique
485	Wang, Q., Li, Q., & Tang, Z.-H. (2019). Sinus floor elevation and simultaneous dental implantation: A long-term retrospective study of sinus bone gain. <i>Beijing da xue xue bao. Yi xue ban = Journal of Peking University Health Sciences</i> , 51(5), 925-930. https://doi.org/10.19738/j.issn.1671-1676.2019.05.022	0	Article in chinese
491	Zili, A., Precht, C., Beck-Broichstetter, B., Sehner, S., Simets, R., Helland, M., Rendebach, C., & Henningsen, A. (2016). Implants inserted with graftless osteotome sinus floor elevation: A 5-year, post-loading retrospective study. <i>European Journal of Oral Implantology</i> , 9(3), 217-289.	0	Only describes graftless technique
505	Nediri, R., Nardin, N., Vazquez, L., Abi Najm, S., & Bischof, M. (2016). Osteotome Sinus Floor Elevation without Grafting: A 10-Year Prospective Study. <i>Clinical Implant Dentistry and Related Research</i> , 18(3), 609-617. https://doi.org/10.1111/clir.12331	0	Only describes graftless technique
507	Magdy, M., Abdelkader, M. A., Aloush, S., Fawry El-Sayed, M. N., Nawwar, A. A., Shoib, M., & ElNahass, H. (2021). Ultra-short versus standard-length dental implants in conjunction with osteotome-mediated sinus floor elevation: A randomized controlled clinical trial. <i>Clinical Implant Dentistry and Related Research</i> , 23(4), 530-539. https://doi.org/10.1111/clir.12995	0	Different objective
512	Shi, J.-Y., Lai, Y.-R., Qian, S.-J., Qiao, S.-C., Tonetti, M. S., & Lai, H.-C. (2021). Clinical, radiographic and economic evaluation of short-6-mm implants and longer implants combined with osteotome sinus floor elevation in moderately atrophic maxilla: A 3-year randomized clinical trial. <i>Journal of Clinical Periodontology</i> , 48(5), 605-614. https://doi.org/10.1111/jcpe.13444	0	Does not mention if a bone graft is added
518	Volpe, S., Larva, M., Verrocchi, D., & Semerly, L. (2013). Clinical outcomes of an osteotome technique and simultaneous placement of resin implants in the posterior maxilla. <i>Clinical Implant Dentistry and Related Research</i> , 15(1), 22-28. https://doi.org/10.1111/1178-8208.2011.00178.x	0	Only describes graftless technique
520	Khaled, H., Atef, M., & Hakam, M. (2019). Maxillary sinus floor elevation using hydroxyapatite nano particles vs tenting technique with simultaneous implant placement: A randomized clinical trial. <i>Clinical Implant Dentistry and Related Research</i> , 21(6), 1243-1251. https://doi.org/10.1111/clir.12959	0	Lateral technique
522	Kakar, A., Sripathi Rao, B. H., Deshpande, N., Hegde, S., Kozhi, A., Patney, A., & Mahajan, H. (2023). Osteotome-mediated sinus floor elevation using an in situ hardening biphasic calcium phosphate bone graft substitute compared to engraft: A randomized controlled clinical trial. <i>Indian Journal of Dental Research: Official Publication of Indian Society for Dental Research</i> , 37(1), 61-68. https://doi.org/10.4103/ijdr.2021.19	0	Only describes bone graft technique
523	Gai, L., Luo, X., Guan, Y., & He, F. (2021). Comparative Evaluation of Endo-Sinus Bone Augmentation After Osteotome Sinus Floor Elevation Without Grafting Using Two Radiographic Methods. <i>The International Journal of Oral & Maxillofacial Implants</i> , 36(1), 154-164. https://doi.org/10.11607/jom.8365	0	Only describes graftless technique
525	Li, P., Piao, M. Z., Hu, H. C., Wang, Y., Zhao, Y. J., & Shen, X. J. (2020). [Radiography study on osteotome sinus floor elevation with placed implant simultaneously with no graft augmentation]. <i>Beijing da xue xue bao. Yi xue ban = Journal of Peking University Health Sciences</i> , 52(1), 95-99. https://doi.org/10.19738/j.issn.1671-1676.2021.01.025	0	Only describes graftless technique
533	Brioua, A., Martin, N., Fernández-González, F. J., Lázaro-Alcalá, C., & Arta, A. (2014). Osteotome sinus floor elevation without grafting material: Results of a 2-year prospective study. <i>Journal of Clinical and Experimental Dentistry</i> , 6(5), 479-84. https://doi.org/10.4317/jced.51276	0	Only describes graftless technique
553	Shi, J.-Y., Gu, Y.-X., Qiao, S.-C., Zhang, L.-F., Zhang, X.-M., & Lai, H.-C. (2015). Clinical evaluation of short 6-mm implants alone, short 8-mm implants combined with osteotome sinus floor elevation and standard 10-mm implants combined with osteotome sinus floor elevation in posterior maxilla: study protocol for a randomized controlled trial. <i>Trials</i> , 16, 284. https://doi.org/10.1186/s13063-015-0863-4	0	Does not mention if a bone graft is added
556	Rao, D. V., Kim, Y.-S., Shin, S.-Y., Kim, W.-K., Lee, Y.-K., & Kim, S.-H. (2015). Clinical Outcomes of Rescan vs Osteotome-Mediated Sinus Floor Elevation with Simultaneous Implant Placement: A 2-Year Retrospective Study. <i>The International Journal of Oral & Maxillofacial Implants</i> , 30(4), 925-930. https://doi.org/10.11607/jom.3779	0	Different objective
559	He, L., Chang, X., & Liu, Y. (2013). Sinus floor elevation using osteotome technique without grafting materials: A 2-year retrospective study. <i>Clinical Oral Implants Research</i> , 24 Suppl A100, 63-67. https://doi.org/10.1111/1600-0501.2013.02376.x	0	Only describes graftless technique
562	El Hage, M., Nardin, N., Abi Najm, S., Bischof, M., & Nediri, R. (2019). Osteotome Sinus Floor Elevation Without Grafting: A 10-Year Study of Cone Beam Computed Tomography in the Periapical Radiography. <i>The International Journal of Periodontics and Restorative Dentistry</i> , 39(1), e89-e97. https://doi.org/10.11607/prd.3777	0	Only describes graftless technique
567	Crespi, R., Cappari, P., & Gherlone, E. (2012). Sinus floor elevation by osteotome: hand drill vs electric mallet. A prospective clinical study. <i>The International Journal of Oral & Maxillofacial Implants</i> , 27(5), 1144-1150.	0	Different objective
568	Chahn, J., Fernández-Rodríguez, R., & Abrahm, J. (2017). Long-term evaluation of osteotome sinus floor elevation and simultaneous placement of implants without bone grafts: 10-year radiographic and clinical follow-up. <i>Clinical Implant Dentistry and Related Research</i> , 19(6), 1023-1033. https://doi.org/10.1111/clir.12530	0	Only describes graftless technique
574	Sanjagata, M., Guarnierello, L., Dramas, S., Tesi, U., Russo, R., & Tartani, G. (2021). Augmentation of atrophic posterior maxilla by short implants and osteotome technique. <i>Stomatologia</i> , 24(3), 85-88.	0	Different objective
575	Kao, H., Yang, Y., Xu, S., Sun, A., & Liu, Z. (2011). Clinical study of osteotome sinus floor elevation without grafting and with simultaneous implants placement. <i>Zhonghua kou qiang yi xue za zhi = Zhonghua kouqiang yixue za zhi = Chinese journal of stomatology</i> , 46(5), 272-275.	0	Only describes graftless technique
577	Gatti, F., Gatti, C., Tallarico, M., Tommasato, G., Meloni, S. M., & Chiappasco, M. (2018). Maxillary Sinus Membrane Elevation Using a Special Drilling System and Hydraulic Pressure: A 2-Year Prospective Cohort Study. <i>The International Journal of Periodontics and Restorative Dentistry</i> , 38(4), 563-569. https://doi.org/10.11607/prd.3463	0	Different objective
580	French, D., Nadjji, N., Shariati, B., Hatrinarafkani, P., & Larjane, H. (2016). Survival and Success Rates of Dental Implants Placed Using Osteotome Sinus Floor Elevation Without Added Bone Grafting: A Retrospective Study with a Follow-up of up to 10 Years. <i>The International Journal of Periodontics and Restorative Dentistry</i> , 36 Suppl, s89-97. https://doi.org/10.11607/prd.3191	0	Only describes graftless technique
598	Galindo-Moreno, P., Fernández-Jiménez, A., Aulia-Gilz, G., Silvestre, F. J., Hernández-Cortés, P., & Wang, K. L. (2014). Marginal bone loss around implants placed in maxillary native bone or grafted sinuses: a retrospective cohort study. <i>Clinical Oral Implants Research</i> , 25(1), 179-186. https://doi.org/10.1111/clor.12122	0	Compares graftless technique with implants in pristine bone
600	Chavakis, R. V., Sawerk, N., & Reddy, A. A. (2018). Trephine Core Procedure Versus Bone-Added Osteotome Sinus Floor Elevation in the Augmentation of the Sinus Floor: A Comparative Clinical and Radiographic Study. <i>The International Journal of Oral & Maxillofacial Implants</i> , 33(2), 427-432. https://doi.org/10.11607/jom.5998	0	Use of bone graft in both techniques
602	Jahodnicka, A., Chicharriani, A., Nijm, A., Nagelbauer, S., Mak, M. S., & Ghorbani, E. M. (2021). Comparison of Bone Formation After Sinus Membrane Lifting Without Graft or Using Bone Substitute: Histologic and Radiographic Evaluation. <i>Journal of Oral and Maxillofacial Surgery: Official Journal of the American Association of Oral and Maxillofacial Surgeons</i> , 79(6), 1246-1254. https://doi.org/10.1016/j.joms.2020.12.040	0	Lateral technique

609	Gonzalez, S., Tian, M.-C., Ahn, K. M., & Nowzari, H. (2014). Crestal approach for maxillary sinus augmentation in patients with a 5 mm of residual alveolar bone. <i>Clinical Implant Dentistry and Related Research</i> , 16(6), 827-835. https://doi.org/10.1111/clin.12067	0	Different objective
611	Verdugo, F., Urbani, A., Laksmanto, T., & D'addona, A. (2017). Long-term stable vertical bone regeneration after sinus floor elevation and simultaneous implant placement with and without grafting. <i>Clinical Implant Dentistry and Related Research</i> , 19(6), 1054-1060. https://doi.org/10.1111/clin.12560	1	
626	Nediri, R., Nurdin, N., Khoury, P., Perneger, T., Hage, M. E., Bernardi, J. P., & Bischof, M. (2013). Osteotome sinus floor elevation with and without grafting material in the severely atrophic maxilla: A 1-year prospective randomized controlled study. <i>Clinical Oral Implants Research</i> , 24(11), 1257-1264. https://doi.org/10.1111/cir.12090	1	
627	Stefanski, S., Svensson, B., & Thor, A. (2017). Implant survival following sinus membrane elevation without grafting and immediate implant installation with a one-stage technique: an up-to-40-month evaluation. <i>Clinical Oral Implants Research</i> , 28(11), 1356-1359. https://doi.org/10.1111/cir.12893	0	Lateral technique
632	Brusch, G. B., Crespi, R., Caparri, P., Bravi, F., Brusch, E., & Gherlone, E. (2013). Localized management of sinus floor technique for implant placement in fresh molar sockets. <i>Clinical Implant Dentistry and Related Research</i> , 15(1), 219-220. https://doi.org/10.1111/clin.12044	0	Different objective
635	Nediri, R., Nurdin, N., Abu Najm, S., El Hage, M., & Bischof, M. (2017). Short implants placed with or without grafting into atrophic sinuses: the 5-year results of a prospective randomized controlled study. <i>Clinical Oral Implants Research</i> , 28(7), 877-886. https://doi.org/10.1111/cir.12829	1	
644	Benylmaz, D. P., & Kasaboglu, O. (2011). Osteotome sinus floor elevation without bone grafting and simultaneous implant placement in the atrophic maxilla: a pilot study. <i>Indian Journal of Dental Research - Official Publication of Indian Society for Dental Research</i> , 22(6), 795-798. https://doi.org/10.4103/0970-9202.950569	0	Only describes graftless technique
653	Rammelsberg, P., Mahabadi, J., Effler, C., Koob, A., Kappel, S., & Gabbert, O. (2015). Radiographic monitoring of changes in bone height after implant placement in combination with an internal sinus lift without graft material. <i>Clinical Implant Dentistry and Related Research</i> , 17(Suppl 2), e267-74. https://doi.org/10.1111/clin.12138	0	Different objective
655	Kim, J. M., Sohn, D. S., Heo, J.-H., Park, J.-O., Jung, W. S., Ahn, J.-W., Lee, H.-H., & Park, I.-S. (2012). Minimally invasive sinus augmentation using ultrasonic piezoelectric vibration and hydraulic pressure: a multicenter retrospective study. <i>Implant Dentistry</i> , 21(6), 536-542. https://doi.org/10.1097/ID.0b013e3182746c3d	0	Different objective
661	Cricchio, G., Imbruglia, M., Sennerby, L., & Lundgren, S. (2014). Immediate loading of implants placed simultaneously with sinus membrane elevation in the posterior atrophic maxilla: a two-year follow-up study on 10 patients. <i>Clinical Implant Dentistry and Related Research</i> , 16(4), 609-617. https://doi.org/10.1111/clin.12035	0	Only describes graftless technique
665	Yang, D.-W., Xiao, J.-Y., Zhang, P., Lu, B.-Y., & Liang, X. (2021). Retrospective study on the merits of bone grafts and the influence of implant production length after osteotome sinus elevation surgery. <i>Xue Yi Xue Qiang Yi Xue Za Zhi = Huo Kouang Yue Zhi = West China Journal of Stomatology</i> , 39(5), 570-575. https://doi.org/10.7518/hkqk.2021.05.012	0	Full-text in chinese
688	Alontas, N. Y., Semel, F. C., Kaymaz, S., Taskesen, F., & Pampou, A. A. (2013). Comparative radiologic analyses of newly formed bone after maxillary sinus augmentation with and without bone grafting. <i>Journal of Oral and Maxillofacial Surgery - Official Journal of the American Association of Oral and Maxillofacial Surgeons</i> , 71(9), 1520-1530. https://doi.org/10.1016/j.joms.2013.04.036	0	Lateral technique
692	Thomas, D. S., Hasan, R., Taha, M., Garcia, A., Salazar-Gil, G., Pietro, A., Hämmerle, C. H. F. (2015). Randomized controlled multicenter study comparing short dental implants (6 mm) versus longer dental implants (11-15 mm) in combination with sinus floor elevation procedures. Part 1: demographics and patient-reported outcomes at 1 year of loading. <i>Journal of Clinical Periodontology</i> , 42(1), 72-80. https://doi.org/10.1111/jcpe.12223	0	Different objective
694	Zhang, Y.-L., Shi, R., Ye, Y.-L., Liu, X.-L., & Li, C. (2013). A clinical study of osteotome sinus floor elevation and simultaneous implant placement in the periodontally compromised patients. <i>Shanghai kou qing yi xue = Shanghai journal of stomatology</i> , 22(4), 423-427.	0	Different objective
747	Nediri, R., Nurdin, N., Khoury, P., & Bischof, M. (2016). Short implants placed with or without grafting in atrophic sinuses: The 3-Year Results of a Prospective Randomized Controlled Study. <i>Clinical Implant Dentistry and Related Research</i> , 18(1), 10-18. https://doi.org/10.1111/clin.12279	0	Different objective
750	Nediri, R., Nurdin, N., Huynh, B. G., & Bischof, M. (2019). Change in Crown-to-Implant Ratio of Implants Placed in Fresh and Kerosin Posterior Maxillary Sinus: A 5-year Prospective Randomized Study. <i>The International Journal of Oral & Maxillofacial Implants</i> , 34(5), 1231-1236. https://doi.org/10.11607/jomi.6766	0	
756	Jiang, Y.-H., Tao, H.-B., Jin, X.-M., & Li, X.-K. (2017). [Clinical evaluation of simple maxillary sinus elevation with simultaneous implant placement in patients with various posterior maxillary deficiency]. <i>Shanghai kou qing yi xue = Shanghai journal of stomatology</i> , 26(6), 633-636.	0	Full-text in chinese
836	Shayesteh, Y. S., Khojasteh, A., Sladati, H., Monzavi, A., Bassiri, S. H., Hossaini, M., & Allahbadi, M. (2013). A comparative study of crestal bone loss and implant stability between osteotome and conventional implant insertion techniques: a randomized controlled clinical trial study. <i>Clinical Implant Dentistry and Related Research</i> , 15(3), 350-357. https://doi.org/10.1111/1708-8208.2011.00376.x	0	Different objective
847	Zhang, X.-M., Shi, J.-Y., Gu, Y.-X., Qiao, S.-C., Mo, J.-J., & Lai, H.-C. (2017). Clinical Investigation and Patient Satisfaction of Short Implants Versus Longer Implants with Osteotome Sinus Floor Elevation in Atrophic Posterior Maxilla: A Pilot Randomized Trial. <i>Clinical Implant Dentistry and Related Research</i> , 19(1), 161-166. https://doi.org/10.1111/clin.12435	0	Only describes graftless technique
862	Rammelsberg, P., Schmitter, M., Gabbert, O., Lorenzo Bermejo, J., Effler, C., & Schwarz, S. (2012). Influence of bone augmentation processes on the long-term success of sinus floor implants. <i>Clinical Oral Implants Research</i> , 23(10), 1232-1237. https://doi.org/10.1111/j.1600-0501.2011.02295.x	0	No comparison
953	Saïman, P., Naamni, N., Jung, R. E., Heik, U., Truogner, T., Hämmerle, C. H. F., Atm, T., & Schmidt, R. (2016). Success of 6 mm implants with Single-Tooth Restorations: A 3-year Randomized Controlled Clinical Trial. <i>Journal of Dental Research</i> , 95(6), 623-628. https://doi.org/10.1177/002204416633432	0	Different objective
1012	Al Qabbani, A., Al Bayatti, S. W., Hasan, H., Samsudin, A. B., Al Kawas, S., Qabbani, A., Al Bayatti, S. W. Al, Hasan, H., Samsudin, A. B., & Kawas, S. A. (2020). Clinical and radiological evaluation of sinus membrane osteotomies subsequent to implant placement. <i>Journal of Craniofacial Surgery</i> , 31(3), e233-e236. https://doi.org/10.1097/SCS.0000000000000616	0	Different objective
1014	Si, M. S., Shou, Y.-W., Shi, Y.-T., Yang, G.-L., Wang, H., & He, F. (2016). Long-term outcomes of osteotome sinus floor elevation without bone grafts: a clinical retrospective study of 8-years. <i>CLINICAL ORAL IMPLANTS RESEARCH</i> , 27(11), 1399-1400. https://doi.org/10.1111/cir.12792	0	Only describes graftless technique
1030	Abi Najm, S., Nurdin, N., El Hage, M., Bischof, M., Nediri, R., Najm, S. A., Nurdin, N., El Hage, M., Bischof, M., & Nediri, R. (2018). Osteotome Sinus Floor Elevation Without Grafting: A 10-Year Clinical and Cone-Beam Sino Assessment. <i>IMPLANT DENTISTRY</i> , 27(4), 458-464. https://doi.org/10.1097/ID.0b013e3182746c3d	0	Only focuses on graftless augmentation
1025	Andrés-García, R., Ríos-Santos, J. V., Herrero-Climent, M., Bullón, P., Fernández-Farhali, J., Gómez-Menchero, A., Fernández-Palacin, A., Ríos-Carrasco, B., Andrés-García, R., Vicente Ríos-Santos, J., Herrero-Climent, M., Bullón, P., Fernández-Farhali, J., Gómez-Menchero, A., Fernández-Palacin, A., & Ríos-Carrasco, B. (2021). Sinus Floor Elevation As an Osteotome Technique without Bone Grafts. <i>INTERNATIONAL JOURNAL OF ORAL AND MAXILLOFACIAL SURGERY AND PUBLIC HEALTH</i> , 28(3). https://doi.org/10.1390/ijomh3103	0	Only focuses on graftless augmentation
1028	Fermegård, B., Åstrand, P., Fermegård, R., & Åstrand, P. (2012). Osteotome Sinus Floor Elevation without Bone Grafts: A 3-Year Retrospective Study with Auto-Tissue Implants. <i>CLINICAL IMPLANT DENTISTRY AND RELATED RESEARCH</i> , 14(2), 198-205. https://doi.org/10.1111/1708-8208.2009.00254.x	0	Only focuses on graftless augmentation
1053	López-Quiles, J., Melero-Alarcón, C., Cano-Duran, J. A., Sánchez-Martínez-Saucedo, E. L., Ortega, R., López-Quiles, J., Melero-Alarcón, C., Cano-Duran, J. A., Sánchez-Martínez-Saucedo, E. L., & Ortega, R. (2018). Maxillary sinus balloon filling and delivered implantation of 50 osseointegrated implants: a prospective, observational, non-controlled study. <i>INTERNATIONAL JOURNAL OF ORAL AND MAXILLOFACIAL SURGERY</i> , 47(10), 1343-1349. https://doi.org/10.1016/j.ijom.2018.04.014	0	Different objective
1061	Bruckmose, E., Gruber, R., Steinmassl, O., Eder, K., Watzinger, F., Bayerle-Eder, M., & Jesch, P. (2018). Crestal Sinus Floor Augmentation Using Hydraulic Pressure and Vibrations: A Retrospective Single Cohort Study. <i>INTERNATIONAL JOURNAL OF ORAL AND MAXILLOFACIAL IMPLANTS</i> , 22(10), 1149-1154. https://doi.org/10.11607/jomi.6478	0	Different objective
1069	Yip, S., Cokar, U., & Rajan, L. (2014). Crest and sinus membrane: an ideal combination for bone regeneration within the maxillary sinuses. <i>DENTAL CADOMOS</i> , 8(4), 281-289.	0	Different objective
1078	Kao, F., Zhao, B. D., Wang, Y., Feng, A. J., Guo, S. W., & Zhang, X. J. (2011). Clinical study of transcrestal maxillary sinus floor elevation with the lift-up sinus retractor. <i>Zhonghua Kou Qiang Yi Xue Za Zhi = Zhonghua Kou Qiang Yue Zhi = Chinese Journal of Stomatology</i> , 46(6), 321-325. https://doi.org/10.3760/cma.j.issn.1002-0098.2011.06.001	0	Different objective
1081	Crespi, R., Toti, P., Covati, U., Crespi, G., & Menchini-Fabris, G. B. G. (2011). Clinical and Radiographic Evaluation of Modified Transalveolar Two-Step Osteotome-Mediated Localized Maxillary Sinus Elevation: A Retrospective. <i>International Journal of Oral and Maxillofacial Implants</i> , 26(1), 553-560. https://doi.org/10.11607/jomi.8573	0	Different objective
1084	Zhao, Y., Yuan, S., Zhou, N., & Ma, Y. (2017). Transcrestal sinus floor augmentation with immediate implant placement applied in three types of fresh extraction sockets: A clinical prospective study with 1-year follow-up. <i>Clinical Implant Dentistry and Related Research</i> , 19(6), 1034-1043. https://doi.org/10.1111/clin.12529	0	Different objective
1087	Ahn, S. H., Park, E. J., & Kim, E. S. (2012). Reamer-mediated transalveolar sinus floor elevation without osteotome and simultaneous implant placement in the maxillary molar area: Clinical outcomes of 981 implants in 380 patients. <i>Clinical Oral Implants Research</i> , 23(7), 866-872. https://doi.org/10.1111/j.1600-0501.2011.02216.x	0	Different objective
1088	Wang, R. F., Zhao, D., Lin, H. Y., Liu, M., & Wang, W. Q. (2018). [Clinical evaluation of two transalveolar methods for sinus augmentation with placing 1204 implants immediately]. <i>Zhonghua Kou Qiang Yi Xue Za Zhi = Zhonghua Kou Qiang Yue Zhi = Chinese Journal of Stomatology</i> , 53(1), 81-85. https://doi.org/10.3760/cma.j.issn.1002-0098.2018.12.006	0	Different objective
1100	Rammelsberg, P., Killan, S., Büsch, C., & Kappel, S. (2020). The effect of transcrestal sinus floor elevation without graft on the long-term prognosis of maxillary implants. <i>Journal of Clinical Periodontology</i> , 47(5), 640-648. https://doi.org/10.1111/jcpe.13378	0	Only describes graftless technique
1110	Fugazzotto, P. A. (2017). Success and Failure Rates of 1.344 6- to 9-mm Length Rough-Surface Implants Placed at the Time of Transalveolar Sinus Elevations, Restored with Single Crowns, and Followed for 60 to 229 Months in Function. <i>The International Journal of Oral & Maxillofacial Implants</i> , 32(6), 1350-1363. https://doi.org/10.11607/jomi.6204	0	Different objective
1127	Lin, S., Feng, Y., Xie, J., Song, Y., Xie, C., & Li, D. (2014). [Maxillary sinus floor augmentation using the transalveolar technique with simultaneous placement of dental implants: a 5-year clinical retrospective study]. <i>Zhonghua Kou Qiang Yi Xue Za Zhi = Zhonghua Kou Qiang Yue Zhi = Chinese Journal of Stomatology</i> , 49(3), 161-165.	0	Different objective
1129	Brusch, G. B., Crespi, R., Caparri, P., & Gherlone, E. (2012). Transcrestal sinus floor elevation: a retrospective study of 46 patients up to 16 years. <i>Clinical Implant Dentistry and Related Research</i> , 14(5), 798-807. https://doi.org/10.1111/1708-8208.2010.00313.x	0	Only describes graftless technique
1131	Thomas, T. J., & Bidra, A. S. (2018). Internal Sinus Membrane Elevation in Patients With Less Than 5 mm Residual Bone Height. <i>Conservative Endodontics or Endodonty (International)</i> , 12(1), 19-25. https://doi.org/10.1111/ced.12146	0	Different objective
1133	French, D., Nadj, N., Liu, S. X., & Larjava, N. (2015). Fractorial classification system for osteotome sinus floor elevation based on an observational retrospective analysis of 926 implants followed up to 10 years. <i>Quintessence International (Berlin, Germany)</i> , 46(10), 823-830. https://doi.org/10.3290/j.ijom.2015.46.10.823	0	Different objective
1137	Zhao, X., Guo, W., & Liu, F. (2018). Clinical evaluation of modified transalveolar sinus floor elevation and osteotome sinus floor elevation in posterior maxilla: study protocol for a randomized controlled trial. <i>Trials</i> , 19(1), 489. https://doi.org/10.1186/s13063-018-2879-x	0	Different objective
1138	Hang, J., Ma, T., Fang, J., & Shi, S. (2018). Radiological Changes Associated with New Bone Formation Following Osteotome Sinus Floor Elevation (OSFE): A Retrospective Study of 40 Patients with 18 Month Follow-Up. <i>Medical Science Monitor: International Medical Journal of Experimental and Clinical Research</i> , 24, 4641-4648. https://doi.org/10.12659/MSM.001079	1	
1141	Poon, A., & Moq, R. K. (2016). Minimally invasive transcrestal guided sinus lift (TSSL): a clinical prospective proof-of-concept cohort study up to 52 months. <i>Clinical Implant Dentistry and Related Research</i> , 18(4), 582-593. https://doi.org/10.1111/clin.12354	0	Different objective
1150	Brusch, G. B., Brusch, E., & Pappert, L. (2011). Flapless Localized Management of Sinus Floor (LMBF) for trans-cresal sinus floor augmentation and simultaneous implant placement: A retrospective non-randomized study 5-year of follow-up. <i>Heliyon</i> , 7(9), e07927. https://doi.org/10.1016/j.heliyon.2021.e07927	0	Different objective
1151	Jain, S., & Soltani, A. (2021). A dynamic surgical navigational approach for immediate implantation and transcrestal sinus augmentation. <i>Journal of Indian Society of Periodontology (Vol. 25, Issue 5, pp. 451-456)</i> . https://doi.org/10.4103/ijsp.ijsp.583_20	0	Different objective
1152	Mahesh, L., Agarwal, A., Guadiso, J. C., Bali, P., & Poon, N. (2019). Survival of implants after indirect Maxillary Sinus Elevation Procedure: A Two Years Longitudinal Study. <i>The Journal of Contemporary Dental Practice</i> , 20(4), 504-507. https://doi.org/10.4103/1097-1729.2019.583277	0	Different objective
1173	Gu, Y.-X., Shi, J.-Y., Zhang, L.-F., Qian, S.-J., Mo, J.-J., & Lai, H.-C. (2016). Transalveolar sinus floor elevation using osteotomes without grafting in severely atrophic maxilla: a 5-year prospective study. <i>Clinical Oral Implants Research</i> , 27(1), 120-125. https://doi.org/10.1111/clin.12447	0	Only focuses on graftless augmentation
1182	Canielli, S., Passarelli, A., Petroni, G., Zanata, A., Testarelli, L., & Cicconetti, A. (2021). Five Years Follow-up of Short Implants Placed in Atrophic Maxilla with Simultaneous Sinus Floor Transcrestal Elevation. <i>Acta Odontologica Scandinavica</i> , 79(3), 171-185. https://doi.org/10.1111/aos.15277	0	Different objective

N*	Cross-searching of cited references	Excluded: 0 Included: 1	Source
1	Marcovic A, Mistic T, Calvo-Guirado, et al. Two-center prospective, randomized, clinical and radiographic study comparing osteotome sinus floor elevation with or without bone graft and simultaneous implant placement. <i>Clin Implant Dent Relat Res</i> . 2016;18:873-882.	1	Reference number 22 of the article: Verdugo, F., Uribarri, A., Laksmna, T., & D'addona, A. (2017). Long-term stable vertical bone regeneration after sinus floor elevation and simultaneous implant placement with and without grafting. <i>Clinical Implant Dentistry and Related Research</i> , 19(6), 1054-1060.
N*	Manual search of international journals	Excluded: 0 Included: 1	Source
1	Trinh HA, Dam VV, Le B, Pittayapat P, Thunyakitpisal P. Indirect Sinus Augmentation With and Without the Addition of a Biomaterial: A Randomized Controlled Clinical Trial. <i>Implant Dent</i> . 2019 Dec;28(6):571-577.	1	Journal: implant dentistry